

Science First

Volume 4, Issue 2

2017

TiUnite®

Setting the scientific standard.
Again.



Cover

Nobel Biocare has set the scientific standard for high level evidence to back our moderately rough TiUnite implant surface.

Background image left: red blood cells and fibrils of the fibrin meshwork over the titanium oxide surface of TiUnite.

Image right: confocal microscopy z-stack projection shows fluorescent staining of fibrin (green), nuclei of white blood cells (blue) and platelets (red) on a TiUnite surface implant (NobelParallel CC).

Contents

TiUnite

TiUnite® – osseointegration	4
TiUnite® – setting the scientific standard	5
Setting the scientific standard. Again.	8
TiUnite® to the top	10
Key study	
Implants with an oxidized surface placed predominately in soft bone quality and subjected to immediate occlusal loading: results from an 11-year clinical follow-up.	12
Ten years of clinical experience with NobelActive®	14
Scientific evidence backs conical connection implants with a TiUnite® surface	17
Key studies	
An open prospective single cohort multicenter study evaluating the novel, tapered, conical connection implants supporting single crowns in the anterior and premolar maxilla: interim 1-year results.	20
Evaluation of a variable-thread tapered implant in extraction sites with immediate temporization: a 3-year multi-center clinical study.	22
Three-year post-loading results of a randomised, controlled, split-mouth trial comparing implants with different prosthetic interfaces and design in partially posterior edentulous mandibles.	24
TiUnite® implants with conical connection – overview of studies	26
References	31

TiUnite® – osseointegration

TiUnite is a high performance implant surface that supports osseointegration – even under the most challenging conditions. It is characterized by a moderately rough thickened titanium oxide layer with high crystallinity and phosphorus content, with ceramic-like properties and micropores. The properties of TiUnite ensure osteoconductivity leading to fast apposition of newly formed bone.

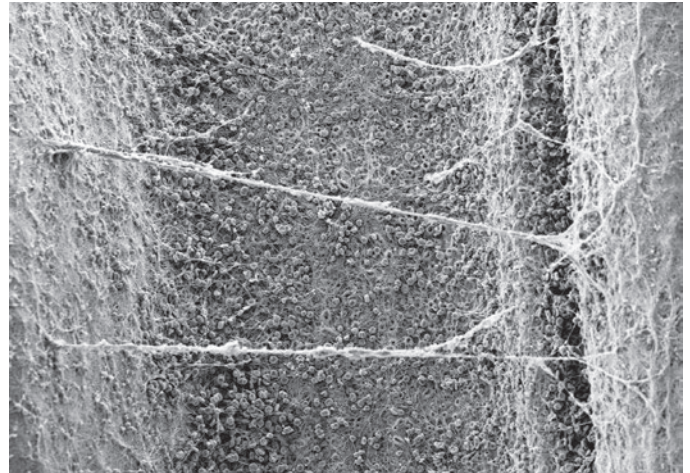
Developed for demanding situations

To address the challenge of increasingly demanding loading protocols, a surface that would speed up bone apposition was needed. The solution was TiUnite – an increased oxide layer formed by spark anodization of the cold-worked, commercially pure grade 4 titanium, altering the chemical composition of the surface and degree of crystallinity.¹ Containing anatase and rutile, TiUnite¹ is associated with greater bone growth compared to both the amorphous and rutile form², and TiUnite provides stronger bone anchorage compared to machined surfaces.^{3,4}

Fast and strong osseointegration

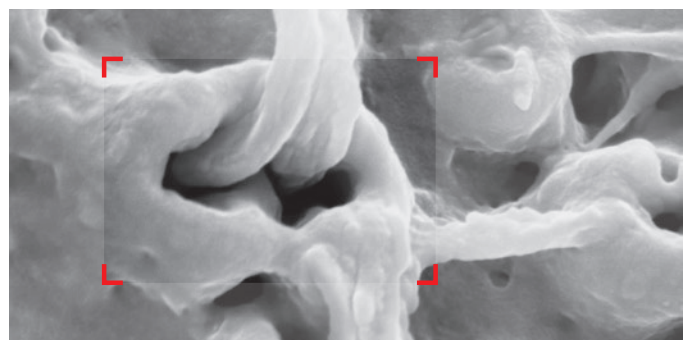
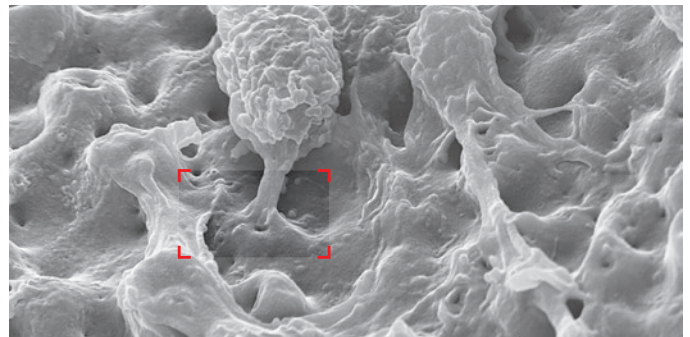
TiUnite's porous surface is an optimized substrate for the migration of osteogenic cells along the surface.⁵ Moreover, the osteoblasts, being polarized cells, secrete collagen matrix only perpendicularly to the surface – and thereby directly into the open TiUnite pores.⁵ This has been shown clinically in trephined-out mini implants in healed sites before placement of traditional implants and restoration.⁶

TiUnite influences the cascade of cellular and molecular processes promoting differentiation of stem cells into osteogenic cells and new bone growth.^{4,7,8} Through early induction of osteoclastic differentiation, TiUnite was shown to accelerate the maturation of the bone-to-implant interface.⁸ This, in turn, led to higher total bone area and bone to implant contact versus machined implants. Stronger upregulation of molecular pathways involved in osteogenesis mimic histological observations and further explain the osteoconductivity of TiUnite and its higher implant stability.^{7,8}



TiUnite is osteoconductive and new bone formation occurs rapidly and directly on and along the implant surface.

Image © 2017 Nobel Biocare Services AG



Bone grows into the pores of TiUnite, resulting in a strong interlock between its surface and bone. Images reproduced with permission. © Schüpbach Ltd, Switzerland.

TiUnite[®] – setting the scientific standard

TiUnite is one of the most clinically researched implant surfaces on the market. Since its launch in 2000, it has been clinically documented in more than 465 publications on 382 clinical studies evaluating more than 89,500 implants, over 22,600 patients, and 11.2 years of longest mean follow-up.^a Now, TiUnite is not only backed by a large quantity of evidence, it is also backed by the strongest evidence – a meta-analysis that confirms high implant survival and stable bone with TiUnite surface.⁹ The superiority of TiUnite compared with machined implants in terms of survival was documented in a previous meta-analysis. More than 19 million implants with TiUnite surface have been sold worldwide.^b Wide scientific and clinical documentation in peer-reviewed journals and the even wider clinical experience with TiUnite implants in patients globally is a testimony to its success.

Key findings of prospective and retrospective clinical studies are:

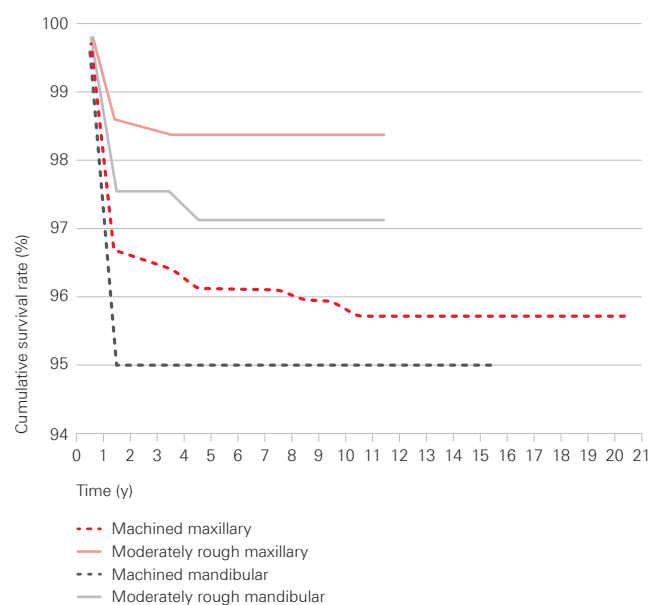
- Proven longevity with clinical follow-up of 10 or more years.¹⁰⁻¹⁴
- Significantly lowered early failure rates upon the introduction of TiUnite compared to historical survival data for machined implants.¹⁵
- Significantly lowered overall risk of failure^{16, 17} without compromise to hard tissue when compared to machined implants.¹⁷
- 97.1 % weighted mean survival in 6 studies with 10–11.2 years' mean follow-up, which compares well to a 97.4 % weighted mean for all studies regardless of follow-up.^a
- Stable marginal bone levels after the initial bone remodeling phase, over the medium and long-term.^{10, 14}

Introduction of TiUnite triggered reduction in early implant failures

In 2001 until 2004, the Brånemark Clinic, Göteborg, Sweden, gradually introduced moderately rough surface implants, primarily TiUnite. In their 28 years of clinical evaluation, 27,914 machined Brånemark implants and 11,163 predominantly TiUnite moderately rough surface implants were placed. Of the moderately rough implants, 10,744 were Brånemark System gradient TiUnite implants, with the remaining implants being an undisclosed number of NobelReplace TiUnite or other moderately rough surface implants.¹⁵ The authors observed that the mean incidence of early failures was 2.1 % when implants with a TiUnite surface were used versus 2.4 % for other moderately rough surfaces.¹⁵ As a result, switching to a moderately rough surface, e.g. TiUnite, was a key contributor to reducing rates of early failure.

Rates of implant failures decreased significantly in the period 2003–2012 compared with 1986–2002, reducing from 11.4 % to 2.1 % in the maxilla, and from 4.5 % to 2.2 % in the mandible ($p < 0.05$).¹⁵ In the same clinic, patient cumulative survival rate (CSR) for maxillary implant placement was 95.8 % for machined surfaces at 15 years' follow-up, and 98.5 % for moderately rough surfaces at 10 years.¹⁶ The survival advantage of predominantly TiUnite moderately rough surfaces seems to continue over time (see figure).

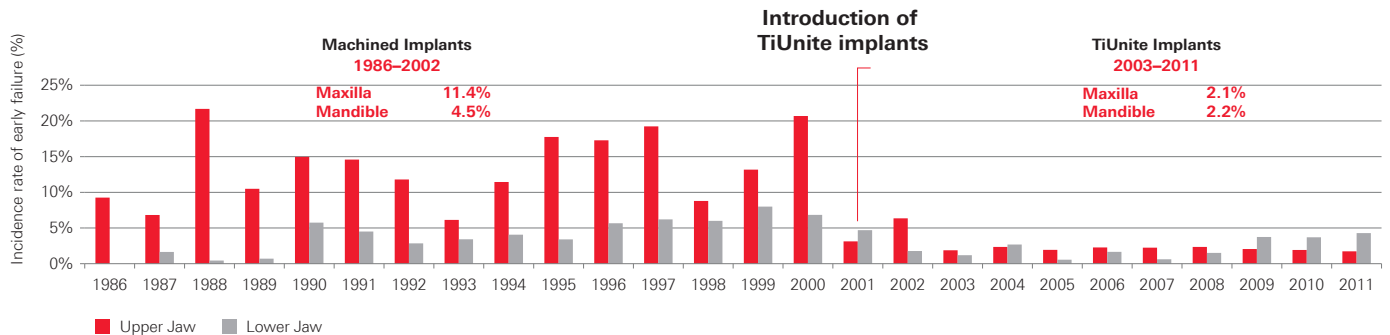
Up to 20 years' survival in single-implant maxillary and mandibular restorations by implant surface



Data from studies comprising >25 patients at last follow-up.¹⁶ Figure reproduced with permission. Copyright © 2016 by Quintessence Publishing Co Inc.

^a TiUnite literature search. Nobel Biocare Services AG. July, 2017.

^b Sales data. Nobel Biocare AG. September, 2017.



Lower incidence of early failures upon the introduction of moderately rough surface, primarily TiUnite surface implants, was significant in both jaws ($p < 0.05$).

Figure courtesy of Professor Torsten Jemt, Sweden.

High survival without compromise to hard tissue

The advantage of TiUnite for implant survival has been continually confirmed over the full breadth of scientific evidence. Looking to a meta-analysis of 38 studies, the relative risk (RR) of implant failure was greater for machined implants versus TiUnite, statistically significant in both jaws: 2.54 times greater in the maxilla and 2.51 times greater in the mandible.¹⁷ There were no statistically significant effects of machined implants on the marginal bone loss (RR 0.02, $p = 0.82$) compared to TiUnite surface implants over the long-term.¹⁷

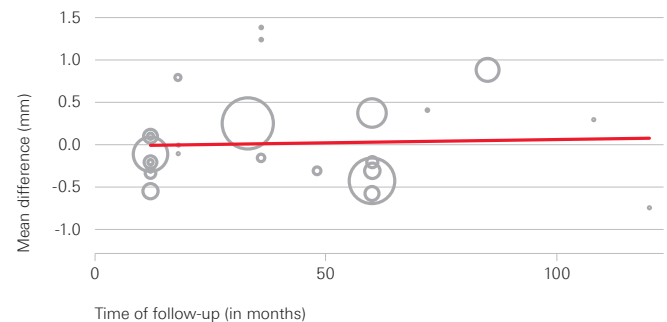
Stable marginal bone levels long-term

Glaser investigated 102 TiUnite surface implants placed predominantly in soft bone and immediately loaded. At 11 years of follow-up, 26 of 38 patients with 66 implants were available for clinical, radiographic and microbiological evaluations.¹⁴ The CSR was 97.1%, with all three implant failures occurring within the first 6 months. After initial bone remodeling during the first year, the mean marginal bone remodeling up to the 11-year follow-up was -0.47 mm, indicating stable bone levels over 10 years.¹⁴

Similarly, Östman et al. reports mean marginal bone change between -0.4 mm at one year, and only -0.3 mm additional bone loss during the subsequent 9 years, and $>99\%$ implant survival at 10 years of follow-up.¹⁰ Patients were partially and fully edentulous, 20% were immediately loaded and 80% followed a staged protocol.¹⁰ If needed, patients were enrolled in an oral hygiene program.

In fact, minimal marginal bone loss after the first year is shown in medium to long-term studies with TiUnite surface implants reporting mean bone level change both at 1 year and latest follow-up. In no studies (see table on page 7) did marginal bone loss exceed -0.1 mm per year, which is well within the established ranges of implant success that have been defined by expert consensus.^{18, 19}

Scatter plot for meta-regression of mean difference in marginal bone loss between machined versus TiUnite surface implants according to follow-up time



Regression analysis shows no differences of marginal bone loss between machined and TiUnite surface implants.¹⁷ Differences were calculated for each study as mean marginal bone loss of machined implants minus mean marginal bone loss of TiUnite surface implants. The sizes of the circles indicates the relative weights of each included study.¹⁷

Figure reproduced with permission. © 2016 John Wiley & Sons Ltd. All rights reserved. No part of this publication may be reproduced in any form or by any means without the express permission from the publisher.

Studies with 5 or more years of follow-up of TiUnite surface implants reporting mean bone level change

Reference	Mean follow-up time [years] ^A	No. of implants	No. of patients	Implant survival rate [%]	Mean marginal bone level change at 1 year [mm]	Mean marginal bone level change at last radiological follow-up [mm] ^C
Glauser, 2016 ¹⁴	11.2	102	38	97.1	-1.16 (±0.9)	-1.66 (±1.0)
Mozzati et al., 2015 ¹²	11	209	90	97.1	NR	-0.60 (±1.2)
Östman et al., 2012 ¹⁰	10	121	46	99.2	-0.40 (±1.6)	-0.70 (±1.4)
Pozzi and Mura, 2014 ²⁰	8.8	167	73	100	NR	-1.58 (±1.6)
Imburgia et al., 2015 ²¹	8.8	205	41	96.1	NR	-0.43 (±1.2)
Froum and Khouly, 2017 ^{22, 23}	8.6	52	28	100	NR	-0.03 (±0.7)
Polizzi et al., 2013 ²⁴	7.5	243	96	96.6	NR	-1.55 (±1.8)
Wagenberg and Froum, 2015 ²⁵	7.4	312	312	100	NR	-0.40 (±0.8)
Gelb et al., 2013 ²⁶	7.3	107	57	100	NR	-1.49 (±1.0)
Turkyilmaz, 2012 ²⁷	7	52	26	100 ^B	NR	-1.31 (±0.2)
Meloni et al., 2017 ²⁸	6	356	66	98	-1.09 (±0.4)	-1.61 (±0.4)
Polizzi and Cantoni, 2015 ²⁹	5.1	160	27	97.33	NR	-1.39 (±1.9)
Alfadda et al., 2009 ³⁰	5	70	35	98.4	NR	-0.40 (±0.4)
Calandriello and Tomatis, 2011 ³¹	5	40	33	95	-0.98 (±0.4)	-1.17 (±0.9)
Cehreli et al., 2010 ³²	5	28	14	100 ^B	NR	-1.20 (±0.1)
Cosyn et al., 2016 ³³	5	22	22	95.5	-0.12 (±0.5)	-0.19 (±0.3)
Lopes et al., 2015 ³⁴	5	92	23	96.6	NR	-1.30 (±1.1)
Malo et al., 2014 ³⁵	5	380	103	99.4	NR	-0.71 (±0.4)
Mura, 2012 ³⁶	5	79	56	100	NR	-0.56 (±2.0)
Pettersson and Sennerby, 2015 ³⁷	5	271	88	99.6	-0.9 (±1.6)	-0.10 (±2.4)

Source: Nobel Biocare data on file (TiUnite Rep 134625, last search December 15, 2016), updated with Nobel Biocare database and PubMed search results for publications in 2016-2017.

A: Where the mean follow-up time was not available the reported follow-up time was used (minimum one-year follow-up).

B: The percentage of surviving implants was calculated.

C: Mean marginal bone level change as reported or calculated. Last radiological follow-up may differ from study follow-up.

NR: Not reported or no single figure could not be calculated from the paper.

Setting the scientific standard. Again.

In the largest ever meta-analysis of a single implant brand, the TiUnite surface has set the scientific standard again, with outcomes from 4,694 clinically evaluated patients treated with 12,804 TiUnite implants reported in 106 prospective studies being analyzed.⁹ The meta-analysis represents the highest-possible level of evidence and unequivocally confirms that the TiUnite implant surface supports peri-implant health, bone maintenance and overall success, long term.

Key findings of the TiUnite meta-analysis:

- Confirmed high early and late survival rates of TiUnite surface implants, exceeding 99% at 1 year and estimated at 95.1% after 10 years, at implant level.⁹
- Low prevalence of peri-implantitis⁹ at a rate comparable with other moderately rough implant surfaces.³⁸
- Estimated marginal bone level change from implant insertion to five-year follow-up is -0.9 mm at implant level and -1.0 mm at patient level.⁹

The highest-level evidence

Meta-analysis combines the results from multiple studies serving to improve the estimate of the size of an effect and to resolve uncertainty surrounding reports that disagree.³⁹ Meta-analysis is the most robust tool at our disposal to evaluate TiUnite implants. It far surpasses observational cohort studies, such as the *Effectiveness of implant therapy analyzed in a Swedish population* and animal studies, such as the *Ligature induced peri-implantitis at implants*, in terms of quality and reliability of evidence.⁴⁰⁻⁴²

Largest ever meta-analysis of a single brand

The study transparently reports patients with TiUnite surface implants prospectively evaluated in a clinical study. Studies reporting on a minimum of 20 patients with at least 12 months' follow-up post-loading were included regardless of protocol, patients' risk profile, or implant design, irrespective of whether or not the implant was still marketed. Prospective studies provide the advantage of proper baseline assessments, longitudinal follow-up and relatively fewer sources of bias. Thirty-two thousand, five hundred and nineteen publications reporting on clinical outcomes with dental implants were screened to ensure inclusion of all of the relevant studies. Of these studies, 106 met the inclusion criteria.⁹



106
prospective studies

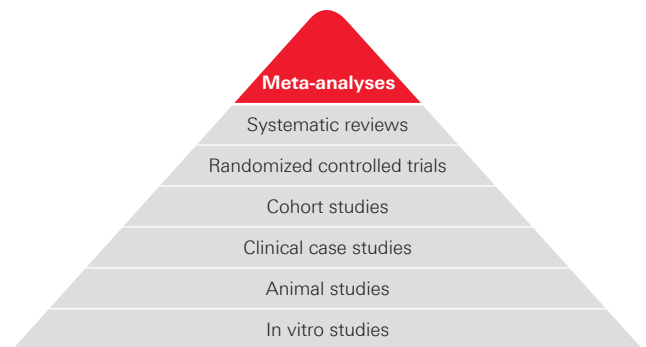


4,694
patients



12,803
TiUnite implants

Strongest evidence



Weakest evidence

32,519

publications screened

No cherry picking

Includes all patients with a TiUnite surface implant prospectively evaluated in a clinical study with a minimum of 20 patients and 12 months post-loading.

Low early failures and high long-term survival

The TiUnite meta-analysis applied regression analysis of survival outcomes of all studies at last available follow-up to create a meaningful projection of implant-level and patient-level survival at multiple time points, as far out as 10 years. These results confirm that implants with the TiUnite surface have a remarkably low early failure rate and very good long-term survival.

One possible limitation of the survival analysis arises from the relatively limited number of studies with long-term survival data available. The quasi-linear shape of the survival curve may, in fact, overestimate the long-term trend in the rate of implant failure. As a result, the survival estimates reported are considered conservative.

Stable marginal bone with all TiUnite surface implants in a wide set of indications

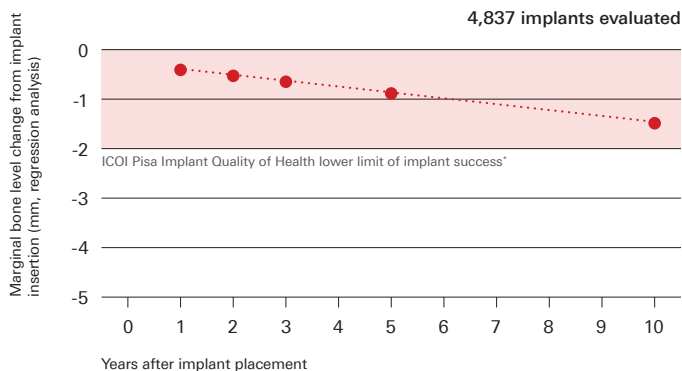
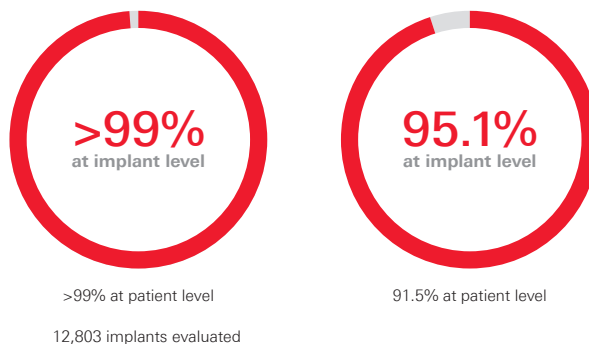
Marginal bone level change from implant insertion to 1, 2, 3, 5 and 10 years was also estimated using regression analysis. Estimates of bone level change from a baseline of implant insertion were -0.4 mm at 1-year follow-up and -0.9 mm at 5-year follow-up, and -1.5 mm at 10 years, at implant level (n=4,837).⁹ These estimates fall comfortably within the <2 mm range from implant insertion that was defined in the expert consensus from the 2008 International Congress of Oral Implantologists (ICOI) in Pisa, Italy, to be a condition of success (i.e. optimum implant health).¹⁸ Within studies, the rate of bone level change typically tapers off after a period of initial remodeling in the first year. As a result, one possible limitation of the meta-analysis may be that any long-term decreases in bone level are overestimated.

These results support TiUnite as a surface that promotes healthy bone response in the first year and stable bone levels long-term.

Low rates of peri-implantitis

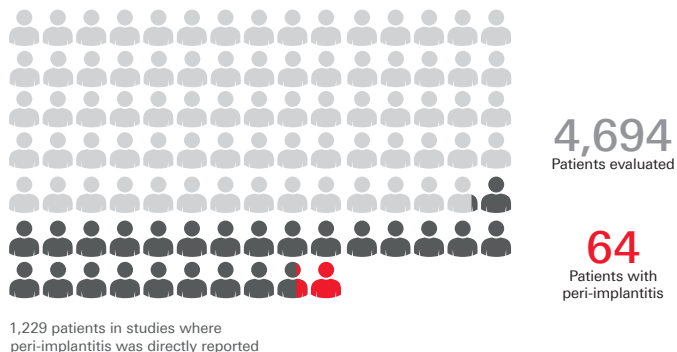
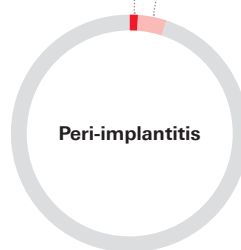
Within the 106 studies, 47 evaluated biological complications, of which 19 studies reported directly cases of peri-implantitis in 64 patients. Using the patient population of the 19 studies as the denominator, the prevalence of peri-implantitis is 5.2% of patients treated with TiUnite surface implants.⁹ Professors Karl and Albrektsson postulated that the actual rate of peri-implantitis among the 4,694 patients in all 106 studies would be as low as 1.36% if peri-implantitis did not occur in studies where it was not reported.⁹ This would be the case supposing clinical investigators had assessed patients and would have reported any findings of peri-implantitis in the other examined studies. This estimate is in line with an earlier report by Albrektsson et al. of 1-2% among modern implants at 10 years.⁴³

1-year implant survival 10-year implant survival



* Misch CE, et al. Implant success, survival, and failure: the International Congress of Oral Implantologists (ICOI) Pisa Consensus Conference. Implant Dent 2008 Mar;17:5-15.

Lowest estimate Highest estimate
1.36% 5.2%



TiUnite® to the top

Clear evidence supports the clinical success of TiUnite to the top of the implant. Clinically, TiUnite supports not only osseointegration, high survival and stable bones long-term, but also soft tissue attachment and healthy soft tissue long-term.

TiUnite supports successful soft tissue integration

Providing protection to the underlying tissue structure, less epithelial downgrowth and a longer connective tissue seal was observed with TiUnite surface implants compared to machined surface.⁴⁴ In one paper, functionally oriented collagen fibers perpendicular to the implant surface were observed; this was unique to TiUnite compared to an acid-etched and a machined surface and may result in a better interface between the implant and the connective tissue.⁴⁵

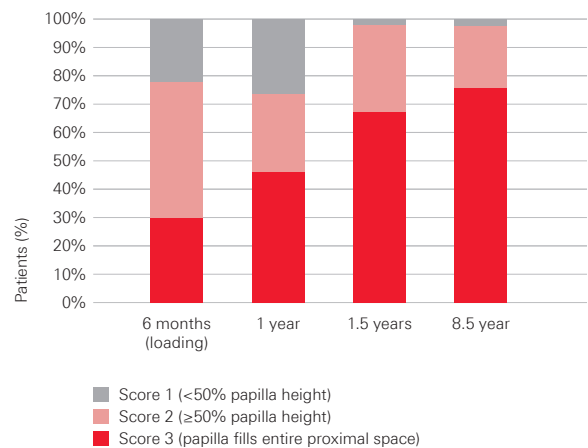
Successful soft and hard tissue outcomes with TiUnite in the soft tissue

While no longer marketed, results with a one-piece NobelDirect implant point towards favorable clinical outcomes, even when the moderately rough TiUnite surface is placed within the soft tissue. Overall bone level change was -0.3 mm at 8.5 years' mean follow-up. After initial remodeling in the first year, a significant bone gain of 0.6 mm was observed from the 1-year to the 8.5-year time point.²² Patients with Jemt papilla index scores of 2 and 3 increased from 6 months to 1.5 years. After 1.5 years, a greater proportion of patients exhibited scores of 3.²² Both soft and hard tissue responses over time showed healthy tissue development in the long run.²²



NobelDirect one-piece implants were placed with 1.5 mm to 2.0 mm of the moderately rough TiUnite surface coronal to the marginal bone.

Proportion of patients with different interproximal papilla height (Jemt scores) over the course of the follow-up period



Major improvements in papilla height occurred between 1 and 1.5 years after implant placement.²²

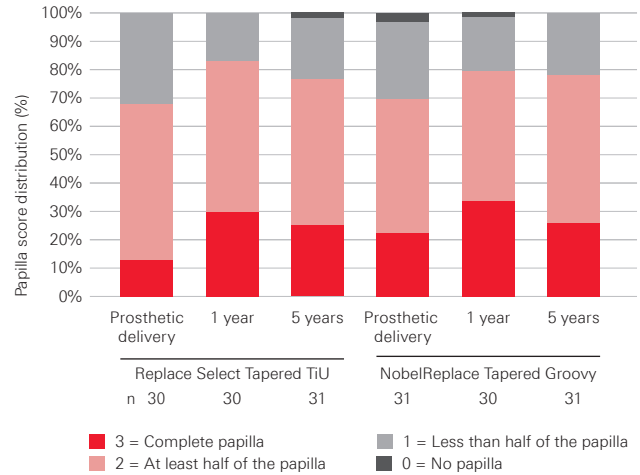
Implant neck design plays a role, but no difference between TiUnite surface implants with or without a machined collar

When TiUnite to the top with a groove (i.e. a textured collar) was compared to a 1.5 mm machined collar,⁴² the total amount of bone loss was $-1.26 (\pm 0.90)$ mm in the machined collar group (Replace Select Tapered TiU), $-1.20 (\pm 1.1)$ mm in the textured collar group (NobelReplace Tapered Groovy), showing no significant differences in the randomized control trial.⁴⁶ Furthermore, no differences were observed in soft tissue outcomes. A third arm of the study not reported here, with scalloped implants (that are no longer marketed) showed significantly poorer clinical outcomes in terms of both hard and soft tissue.

Determinants of bone remodeling

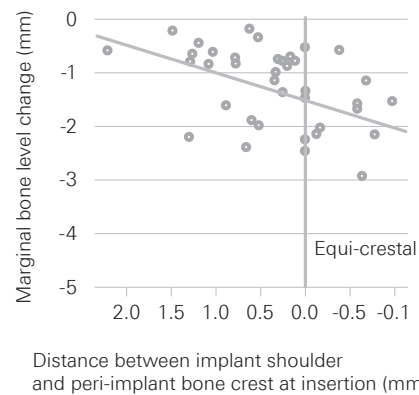
Whether the collar is TiUnite with grooves or machined, depth of implant placement relative to the crest of the bone may be the key determinant of bone remodeling.⁴⁷ In an observational pilot study with TiUnite surface implants, 20 patients received Replace Select Tapered TiU implants with a 1.5 mm machined collar, and 20 patients received NobelReplace Tapered Groovy, which has a textured collar, i.e. TiUnite to the top.⁴⁷ There were no differences in marginal bone change between the machined versus the textured collar group at 12–18 months. A power calculation determined that 2,064 patients would be required to embark on a full study, and would therefore not be feasible.⁴⁷ Only increased depths of implant insertion relative to the bone crest exhibited a statistically significant impact on the amount of bone remodeling surrounding the implants.

Papilla height (Jemt scores) from definitive crown placement to 1 and 5 years



No significant differences were observed in soft tissue outcomes, or in bone remodeling, with the textured collar compared to a 1.5 mm machined collar.⁴⁶

Relationship between depth of implant placement (supra-, equi- or sub-crestally) with marginal bone level change



Greater implant insertion depths were associated with greater peri-implant marginal bone loss (rank correlation coefficient -0.46).⁴⁷

Copyright © 2014 by Quintessence Publishing Co Inc.

Implants with an oxidized surface placed predominately in soft bone quality and subjected to immediate occlusal loading: results from an 11-year clinical follow-up

Glauser R

Clin Implant Dent Relat Res 2016;18(3):429–438.

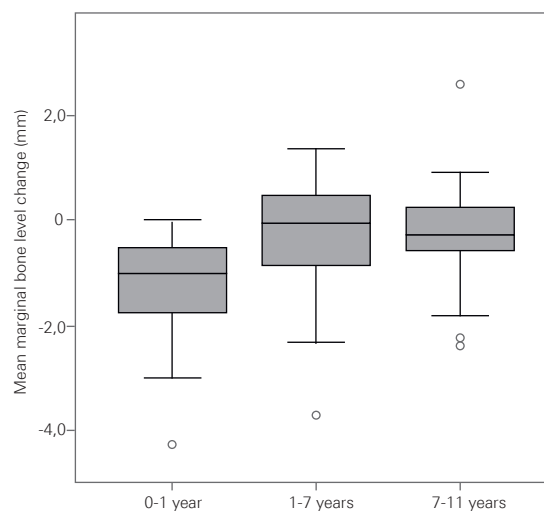
Results of life table analysis

Time period	Implants	Failed	Withdrawn	CSR (%)
Implant insertion to 6 months	102	3	0	97.1
6 months to 1 year	99	0	0	97.1
1 year to 2 years	99	0	4	97.1
2 years to 3 years	95	0	5	97.1
3 years to 5 years	90	0	0	97.1
5 years to 7 years	90	0	13	97.1
7 years to 11 years	77	0	11	97.1
11 years	66	–	–	–

All three (3) failed implants were placed in the maxilla in one patient and were reported as failures at the same visit.

CSR = cumulative survival rate.

Marginal bone level changes (mm) between implant placement (loading) and 1 year, 1 and 7 years, and between 7 and 11 years' follow-up



Number of prostheses and implants per indication

	Indication					
	Single anterior maxilla	Single posterior maxilla	Single posterior mandible	Partial posterior maxilla	Partial posterior mandible	Complete mandible
Reconstructions	5	7	8	10	20	1
Implants	5	7	8	26	51	5
Failures	–	–	–	3	–	–

Original abstract

Purpose: The purpose of this clinical follow-up was to document the 11-year outcome of implants with a moderately rough oxidized surface subjected to immediate occlusal loading.

Materials and methods: Twenty-six of 38 patients enrolled in a 5-year prospective study were available for this follow-up analysis, with 33 restorations supported by 66 slightly tapered implants (Brånemark System Mk IV, Nobel Biocare, Gothenburg, Sweden). The majority of implants were placed in posterior regions (88%) and into soft bone (76%). Parameters included cumulative survival rate, radiographic marginal bone level, bleeding on probing, intrasulcular counts of periopathogenic markers (DNA probes), and total bacterial load.

Results: The cumulative survival rate was 97.1% at 11.2 years' mean follow-up. Mean marginal bone remodeling was 0.47 mm (SD 1.09, n = 65) from 1 year postplacement to 11-year follow-up. Bleeding on probing was absent at most sites (63.6%). No statistically significant differences in total bacterial load or periopathogenic marker species were observed at implants and teeth.

Conclusion: The results of the present follow-up show high long-term survival, stable marginal bone levels, and soft tissue outcomes of oxidized surface implants placed predominately in posterior regions and soft bone. The quantity and quality of intrasulcular microbiota were comparable at implants and teeth.

Reproduced with permission. © 2015 Wiley Periodicals, Inc. All rights reserved. No part of this publication may be reproduced in any form or by any means without the express permission from the publisher.

Ten years of clinical experience with NobelActive®

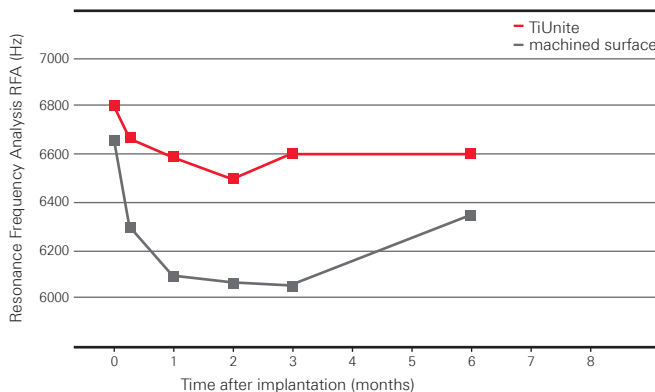
The innovation of NobelActive represented a breakthrough in implant design, harmonizing biomedical engineering expertise with the clinical needs and the wisdom of clinicians. NobelActive's expanding tapered implant body condenses bone gradually while the apex with drilling blades enables a smaller osteotomy. These features help to achieve high primary stability in demanding situations, such as soft bone or extraction sockets.

Perfect harmony of implant surface, drilling protocol and geometric design

The TiUnite surface combined with the NobelActive surgical protocol, tapered apex and threads from tip to platform are all designed to provide high primary stability and support immediate loading. Reverse-cutting flutes with drilling blades on the apex enable experienced clinicians to adjust the implant position during placement for an optimized restorative orientation, particularly in extraction sites. NobelActive's back-tapered coronal design and built-in platform shifting are designed to optimize bone and soft tissue volume for natural-looking esthetics.

The osteoconductive properties of TiUnite, supporting fast apposition of newly formed bone, helps ensure that high stability achieved at implant insertion can be maintained throughout the critical healing phase. Clinically, this relationship between the osteoconductive effect of the TiUnite surface and implant stability in patients with predominantly soft bone was confirmed by Glauser et al, with Brånemark IV implants.⁴⁸ Their study showed higher stability compared with machined implants of the same macro-geometry;⁴⁸ results were statistically significant at 1, 2 and 3 months following immediate loading after implant insertion.

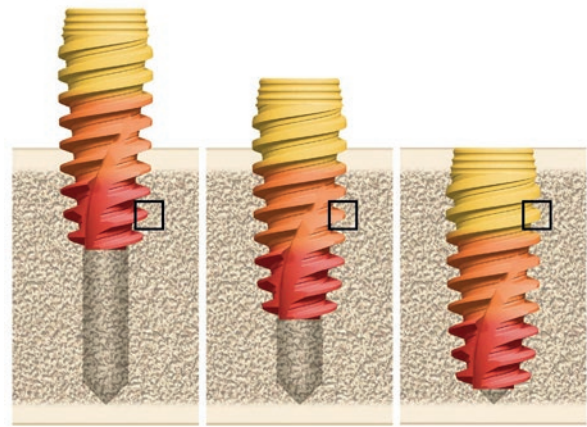
High stability in the critical healing phase allows for Immediate Function




Higher stability with immediately loaded TiUnite surface implants (external hexagonal connection) than with the same implants with machined surface in the posterior maxilla.⁴⁴

The conical connection of NobelActive seems to have an advantage against leakage. Conical connection implants, including Nobel Biocare's conical connection, showed lower bacterial leakage compared to flat connections, in an in vitro model.⁴⁹

High primary stability in demanding situations, such as soft bone or extraction sockets



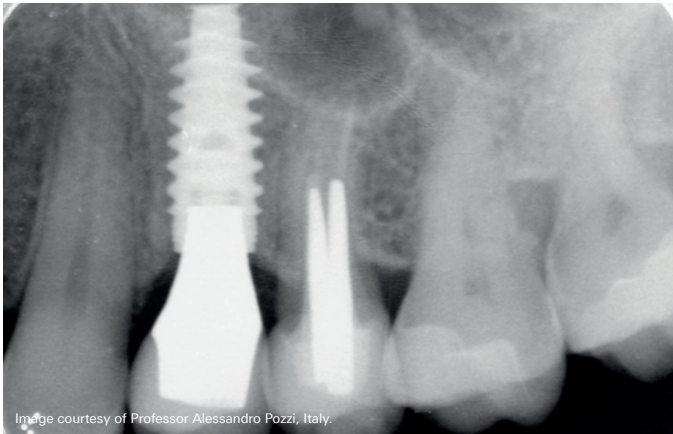
NobelActive's expanding tapered implant body condenses bone gradually while the apex with drilling blades enables a smaller osteotomy.



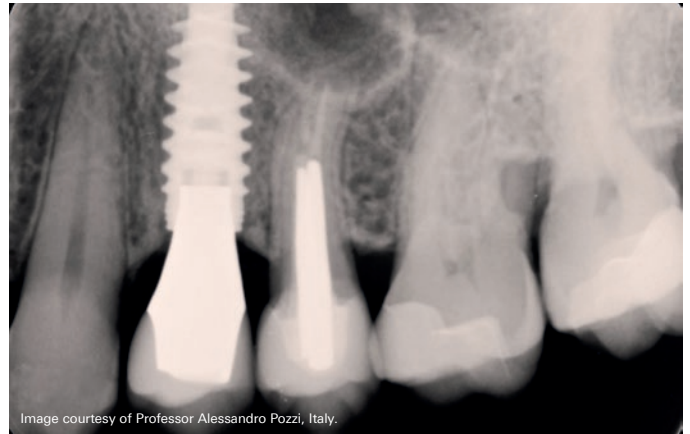The included NobelActive Conical Connection implants with Snappy Abutment showed no leakage in this model.⁴⁹

Clinical case – NobelActive supporting hard and soft tissue for 10 years

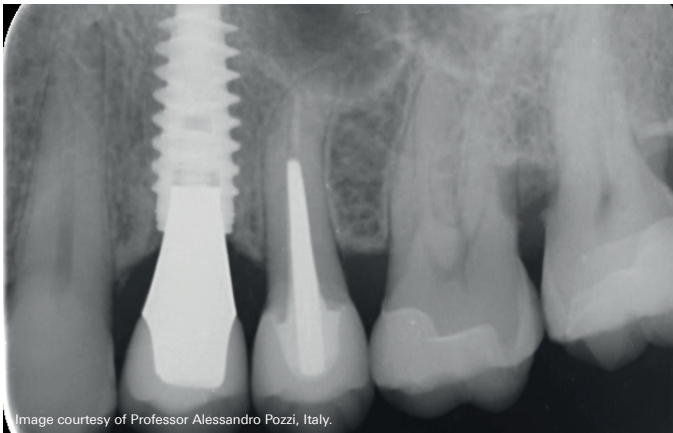
Immediate implant placement in a fresh extraction socket of a NobelActive RP implant 4.3 mm × 13 mm. Socket augmentation was performed, using xenograft and autogenous soft tissue grafting harvested from the tuberosity area, to close the socket and increase the amount of soft tissue at the recipient site. A cement-retained lithium disilicate crown was cemented onto an anatomically shaped zirconia abutment.



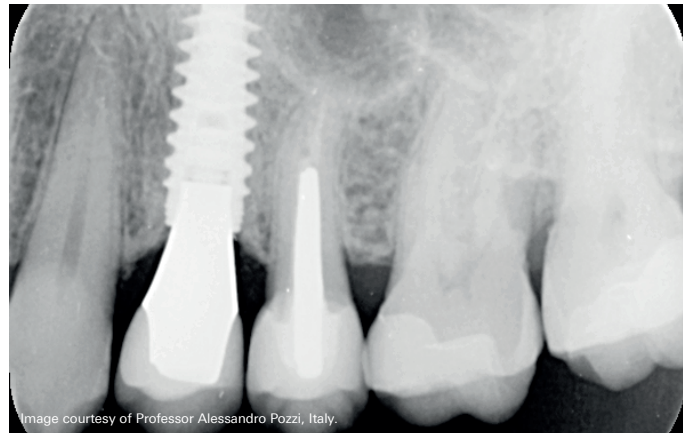
Radiological outcome with NobelActive at 1-year follow-up, showing stable bone.



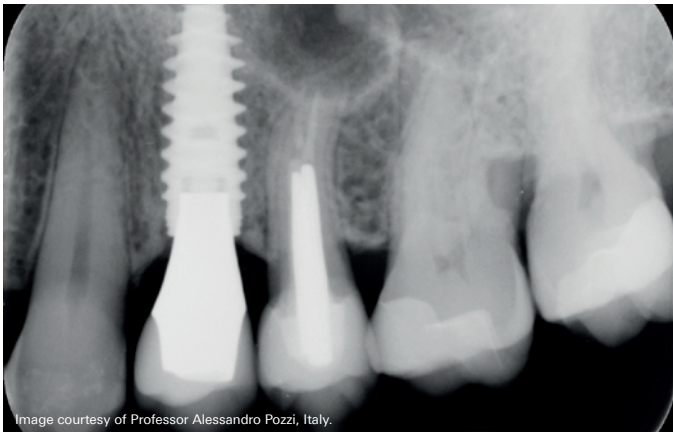
Radiological outcome with NobelActive at 7-year follow-up, showing stable bone.



Radiological outcome with NobelActive at 3-year follow-up, showing stable bone.



Radiological outcome with NobelActive at 9.5-year follow-up, showing bone overgrowth over time onto the implant platform.



Radiological outcome with NobelActive at 5-year follow-up, showing stable bone.

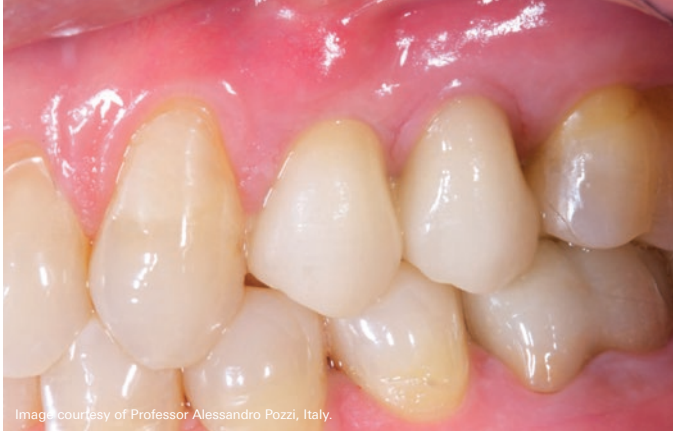

Image courtesy of Professor Alessandro Pozzi, Italy.

Clinical outcome with NobelActive at 1-year follow-up, showing healthy papilla.

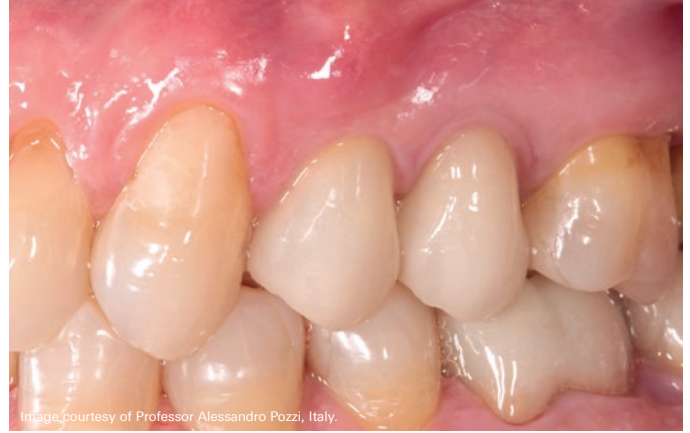

Image courtesy of Professor Alessandro Pozzi, Italy.

Clinical outcome with NobelActive at 7-year follow-up, showing healthy papilla.

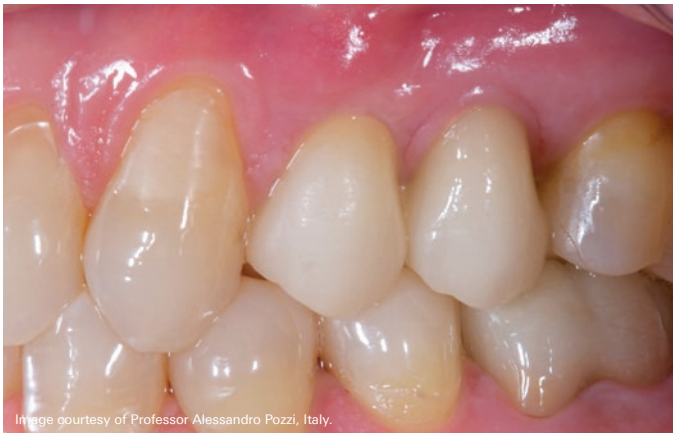

Image courtesy of Professor Alessandro Pozzi, Italy.

Clinical outcome with NobelActive at 3-year follow-up, showing healthy papilla.

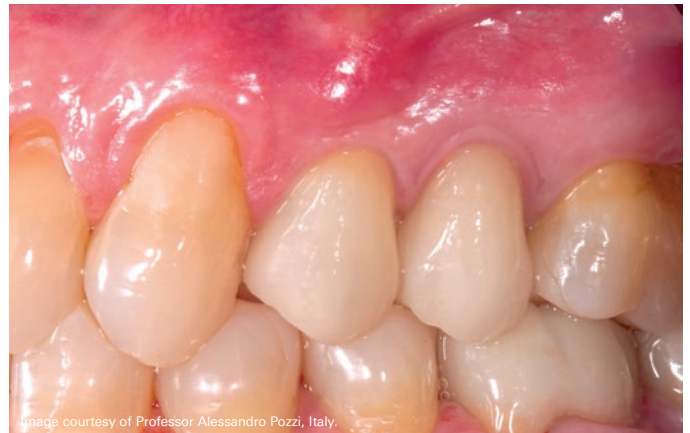

Image courtesy of Professor Alessandro Pozzi, Italy.

Clinical outcome with NobelActive at 9.5-year follow-up.

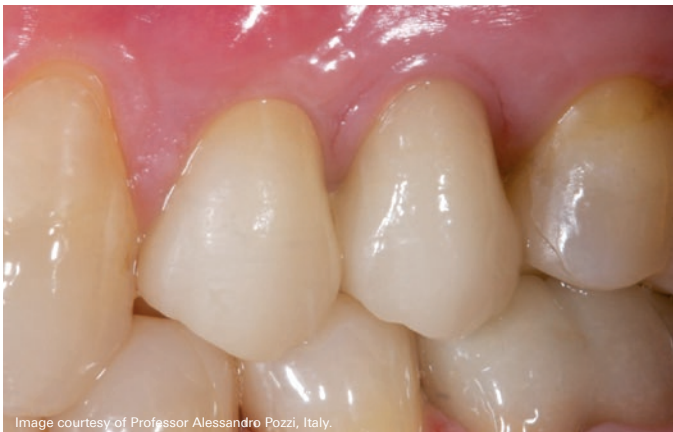

Image courtesy of Professor Alessandro Pozzi, Italy.

Clinical outcome with NobelActive at 5-year follow-up, showing healthy papilla.

Scientific evidence backs conical connection implants with a TiUnite® surface

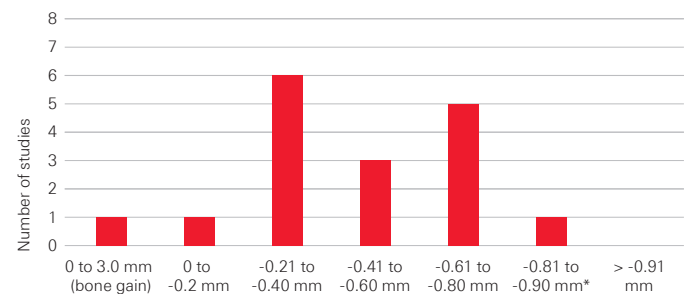
The conical connection is a strong connection designed to benefit the soft and hard tissue parameters. Nobel Biocare's conical connection was introduced with the NobelActive implant in 2008. Since then, over 14,000 NobelActive implants with conical connection and almost 500 NobelReplace Conical Connection implants in over 2,700 patients have been clinically evaluated in 45 clinical studies (see tables on pages 26 to 30).

Key findings of clinical studies with NobelActive are:

- Studies reporting mean marginal bone level change with NobelActive implants show minimal bone remodeling in the healing phase followed by stable or increasing bone levels.^{33, 50-52}
- The implant design and conical connection with built-in platform shifting result in less crestal bone change.^{51, 52}
- Papilla size significantly improves during the first year, and from implant insertion until 3 and 5 years.^{33, 50}
- The unique implant design ensures high primary stability even in soft bone and fresh extraction sockets.^{33, 50, 52-54}
- Studies show that NobelActive is a reliable implant for Immediate Function protocols,^{50, 53, 55} as well as challenging cases such as severely atrophic maxilla.^{56, 57}
- NobelActive is also successful with full-arch restorations with the All-on-4® treatment concept.^{57, 58}

Nineteen studies with 1 to 5 years' follow-up have evaluated bone level change with NobelActive implants. There is a clear trend toward lower bone remodeling with NobelActive compared to historical data with TiUnite surface implants without a conical connection. No study with a minimum of 1-year and up to 5-years of follow-up had a bone remodeling of over -0.89 mm.^{59, 60} Thus, looking to the middle point in the graph, one may expect mean bone remodeling with NobelActive implants to be approximately -0.4 mm at up to 5 years of follow-up. This further speaks to the crucial inter-relationship between implant surface, drill protocols and geometrical design and their synergistic effect on implant treatment outcomes.

Studies report mean marginal bone level change from implant insertion with NobelActive implants



* Excludes a single study that evaluated a predecessor NobelActive implant that was not made commercially available, which had a slightly different connection and back taper design.

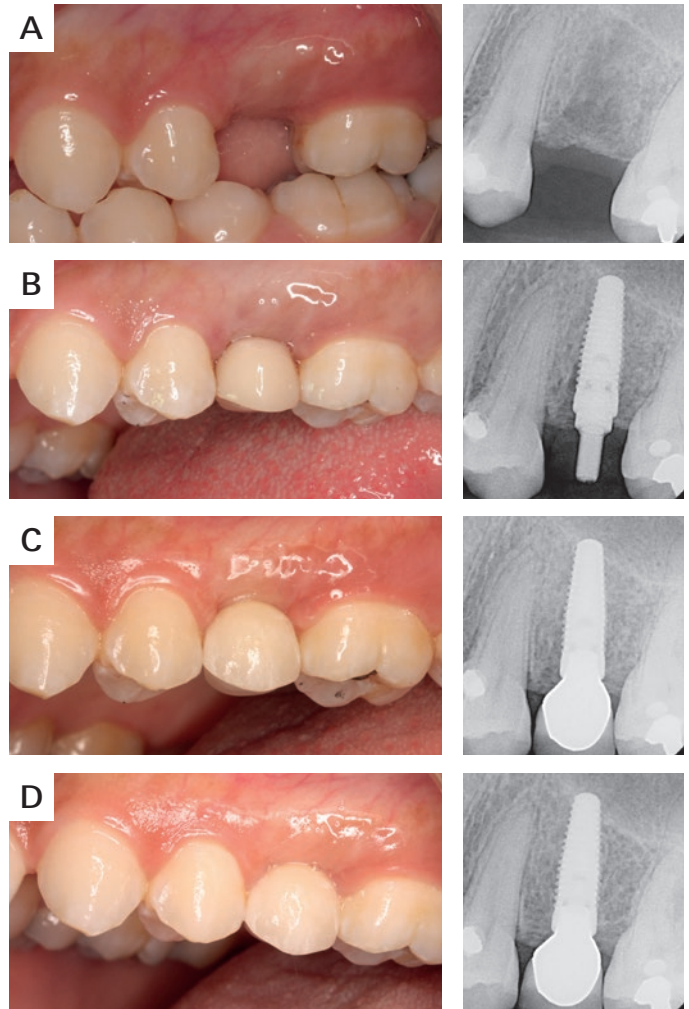
Key findings of clinical studies with NobelReplace Conical Connection are:

- High implant survival in single tooth, partially edentulous and fully edentulous indications.^{20, 61}
- Good performance in both healed and extraction sites.²⁰
- Stable bone levels after the initial bone remodeling of the healing period.⁶¹
- Good soft tissue outcomes and healthy papilla development over the first year.⁶¹

Data with NobelReplace Conical Connection implants has reached critical mass to evaluate clinical outcomes. Six clinical studies report survival rates between 98.3% and 100% at 1 to 3 years of mean follow-up. Weighted mean bone level change was -0.71 mm (see table on pages 26 to 30). In a study evaluating 72 patients, NobelReplace Conical Connection performed well in both healed ($n=81$) and post-extraction sites ($n=67$) with 99.3% implant and 100% prosthesis survival rates.²⁰ A multi-center prospective single-tooth study showed 99% cumulative survival rate at 1 year.⁶¹ Improving Jemt papilla index scores over time, partially or fully gained papilla was observed at 30.8% of sites at baseline, 87.2% at 6 months, and 90.5% at 1 year.⁶¹ After the initial 6-month remodeling period, bone gain observed until the 1-year follow-up of this study.⁶¹

Experience with NobelReplace Conical Connection covers a number of indications. For edentulous patients, four NobelReplace Conical Connection implants to support a CAD/CAM NobelProcera bar supporting an overdenture has shown success.⁶² The bar was positioned with 1 mm clearance for easy oral hygiene maintenance and as a result, hygiene was maintained by patients with only slight plaque at 6.9% of implants.⁶² One year mean marginal, bone level change was low at -0.29 mm and patients experienced a significant improvement of quality of life.⁶²

A representative clinical case, position 25



Clinical view and periapical radiograph prior to surgery (a), at implant insertion (b), at final crown delivery (c), and 1 year after implant placement (d).

© 2016 The authors. Reproduced and distributed under the terms of the Creative Commons Attribution 4.0 International License (<http://creativecommons.org/licenses/by/4.0/>).

Clinical case with the recently introduced NobelParallel CC implant

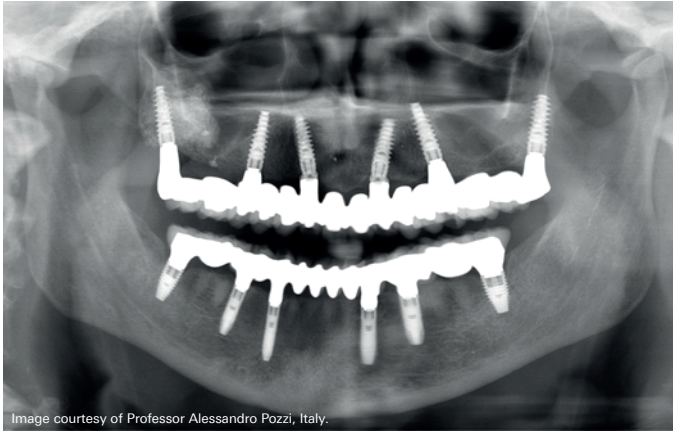


Image courtesy of Professor Alessandro Pozzi, Italy.

Radiograph of fully edentulous patient restored with NobelActive implants in the maxilla at 8 years and NobelParallel CC implants in the mandible at 2 years of follow-up.

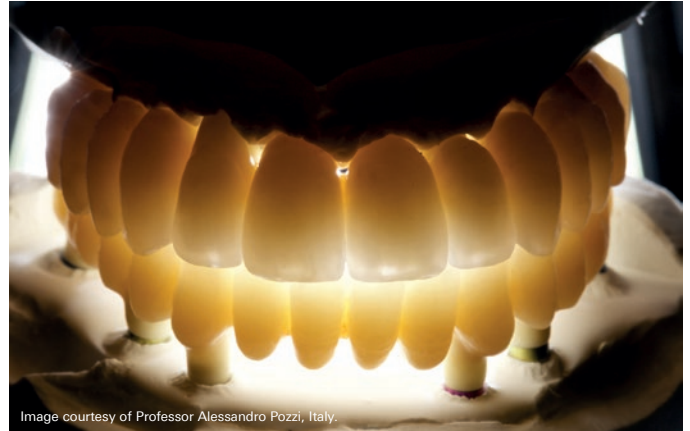

Image courtesy of Professor Alessandro Pozzi, Italy.

The patient was restored with NobelProcera implant bridge zirconia.

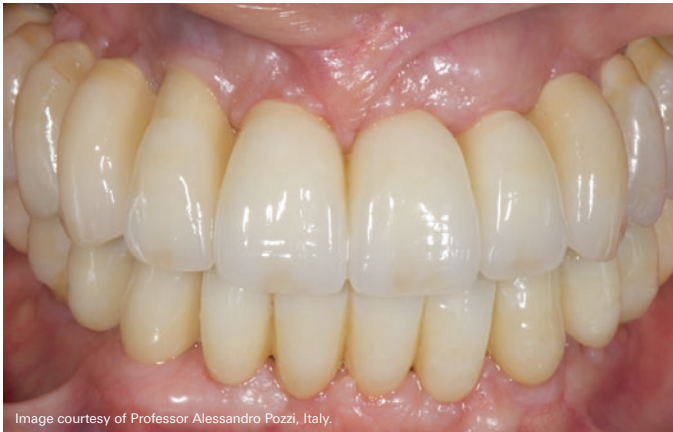

Image courtesy of Professor Alessandro Pozzi, Italy.

Clinical image with NobelProcera implant bridge zirconia.

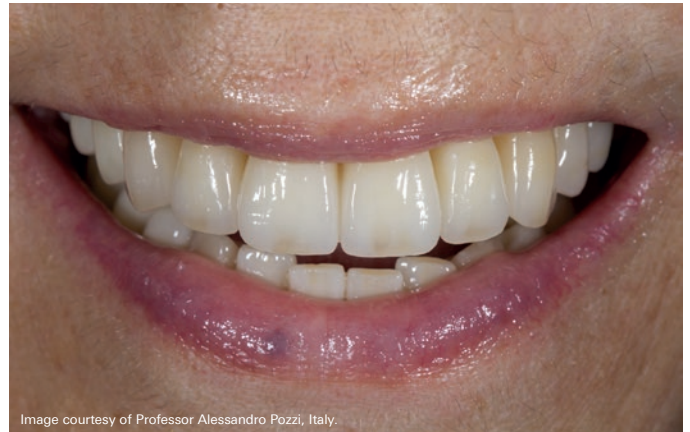

Image courtesy of Professor Alessandro Pozzi, Italy.

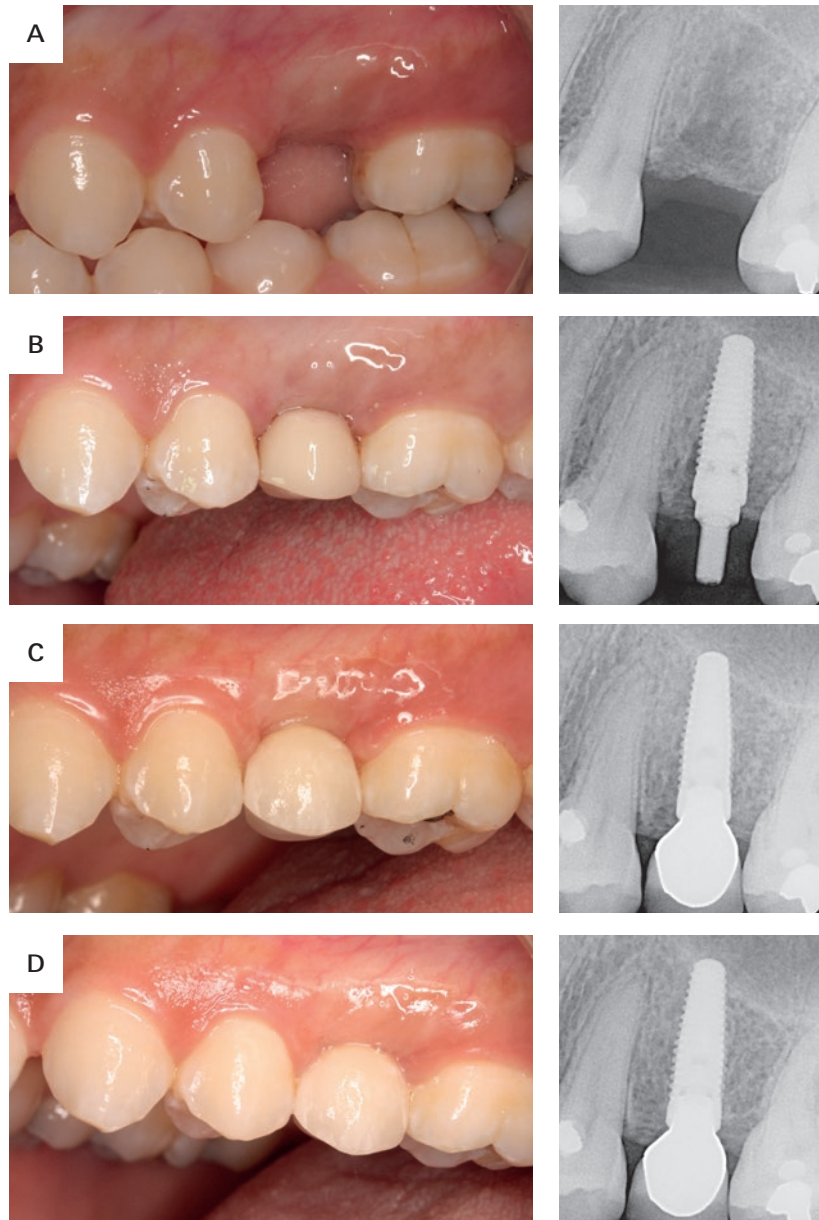
Excellent esthetic outcome.

An open prospective single cohort multicenter study evaluating the novel, tapered, conical connection implants supporting single crowns in the anterior and premolar maxilla: interim 1-year results

Fügl A, Zechner W, Pozzi A, Heydecke G, Mirzakhani C, Behneke N, Behneke A, Baer RA, Nölken R, Gottesman E, Colic S

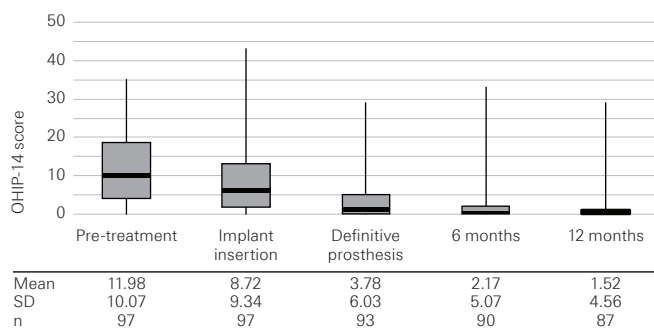
Clin Oral Investig 2017;21(6):2133–2142

A representative clinical case, position 25



Clinical view and periapical radiograph prior to surgery (a), at implant insertion (b), at final crown delivery (c), and 1 year after implant placement (d).

OHIP-14 scores throughout the study.



The black marker lines indicate the median and the boxes signify the first and third quartiles. Bars indicate minimum and maximum value. Mean, standard deviation (SD), and sample number per time point (n) are listed below the graph.

Marginal bone level changes throughout the study period

	Insertion to 6 months	Insertion to 1 year	6 months to 1 year
Mean (mm)	-0.94	-0.85	0.11
SD (mm)	1.32	1.37	1.06
n	84	80	83
p	<0.0001	<0.0001	0.0808

Original abstract

Objectives: The aim of this multicenter prospective clinical study was to evaluate anodized tapered implants with a conical connection and integrated platform shifting placed in the anterior and premolar maxilla.

Materials and methods: The study enrolled patients requiring single-tooth restorations in healed sites of maxillary anterior and premolar teeth. All implants were immediately temporized. Clinical and radiographic evaluations were conducted at implant insertion, 6 months, and 1 year. Outcome measures included bone remodeling, cumulative survival rate, success rate, soft-tissue health and esthetics, and patient satisfaction. Bone remodeling and pink esthetic score were analyzed using Wilcoxon signed-rank tests. CSR was calculated using life table analysis. Other soft-tissue outcomes were analyzed using sign tests.

Results: Out of 97 enrolled patients (102 implants), 87 patients (91 implants) completed the 1-year visit. Marginal bone remodeling was -0.85 ± 1.36 mm. After the expected initial bone loss, a mean bone gain of 0.11 ± 1.05 mm was observed between 6 months and 1 year. The cumulative survival rate was 99.0%, and the cumulative success rate was 97.0%. Partial or full papilla was observed at 30.8% of sites at baseline, 87.2% at 6 months, and 90.5% at 1 year. Soft-tissue response, esthetics, and patient satisfaction all improved during the study period.

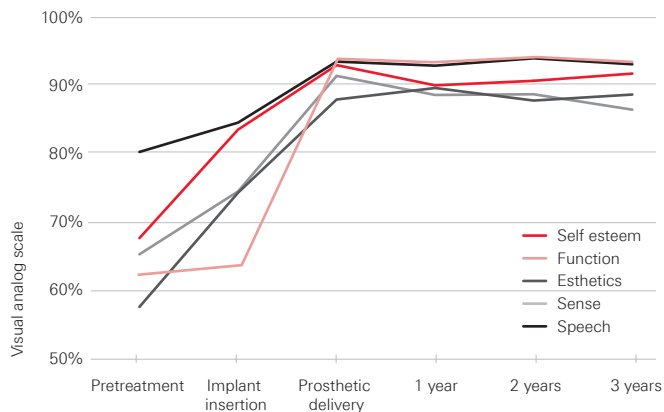
Conclusions: Bone gain was observed following the expected initial bone loss, and soft-tissue outcomes improved suggesting favorable tissue response using anodized tapered conical connection implants.

Clinical relevance: Rapid stabilization of bone remodeling and robust papilla regeneration indicate favorable tissue healing promoted by the conical connection, platform-shift design. Trial registration: [clinicaltrials.gov NCT02175550](https://clinicaltrials.gov/NCT02175550).

Evaluation of a variable-thread tapered implant in extraction sites with immediate temporization: a 3-year multi-center clinical study

Kolinski ML, Cherry JE, McAllister BS, Parrish KD, Pumphrey DW, Schroering RL

J Periodontol 2014;85(3):386–394.

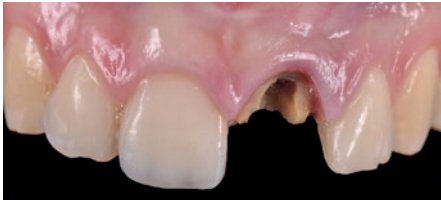

Significant improvements in patient self-ratings right after implant insertion and at delivery of the final prosthesis.¹

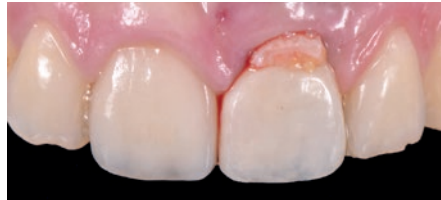Summary of the study

Kolinski et al. (2014) report excellent results: high CSR, stable bone levels, good soft tissue health and patient satisfaction using NobelActive implants. A total of 60 implants were placed in 55 patients at 6 centers, all in extraction sites and subjected to Immediate Function. Patients requiring major bone augmentations were excluded, while minor augmentations were permitted. CSR after 3 years was 98.3%. Bone levels were exceptionally stable: Bone remodeling of a mere -0.2 mm during the first 6 months quickly stabilized and showed even a non-significant bone gain of 0.3 mm at 3 years. Papilla scores increased significantly ($p < 0.001$) from insertion to 3-year follow-up, with most of the increase occurring during the first year. The results on quality of life are also noteworthy, with significant improvements in patient self-ratings on esthetics, self-esteem, function, sense and speech. The authors therefore conclude that NobelActive can be used safely and effectively under demanding conditions such as immediate tooth replacement in extraction sites – not only with regards to CSR and hard- and soft-tissue health, but also in terms of patient satisfaction.

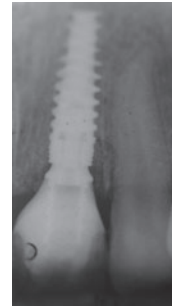
Clinical case – Excellent esthetic outcome at 8-year follow-up with Immediate Loading on a NobelActive implant



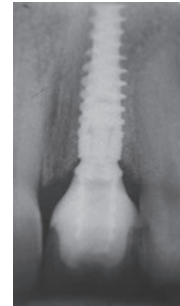Clinical situation before treatment.



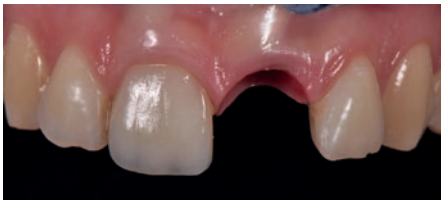Clinical view of temporary after surgery (Immediate Loading).



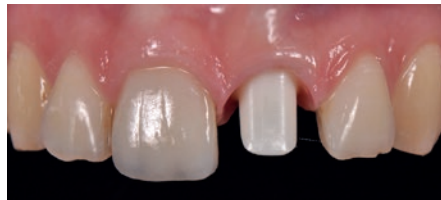Radiograph showing temporary after surgery (Immediate Loading).



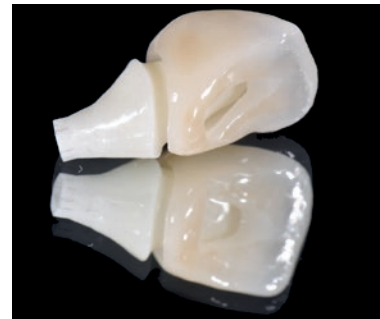Radiograph showing temporary after 3 months.



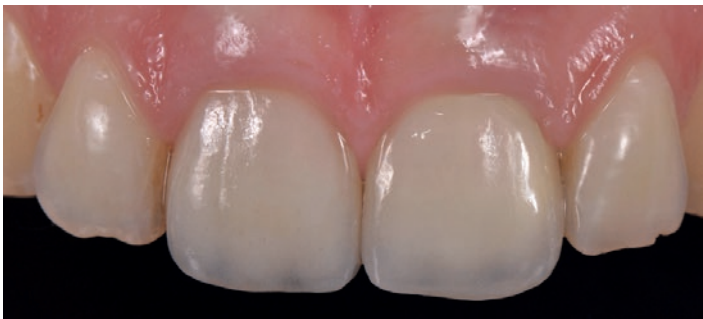Clinical view of soft tissue before finalization.



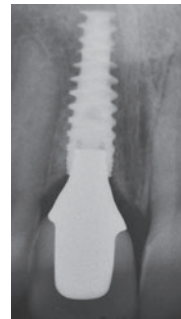Zirconia abutment in situ.



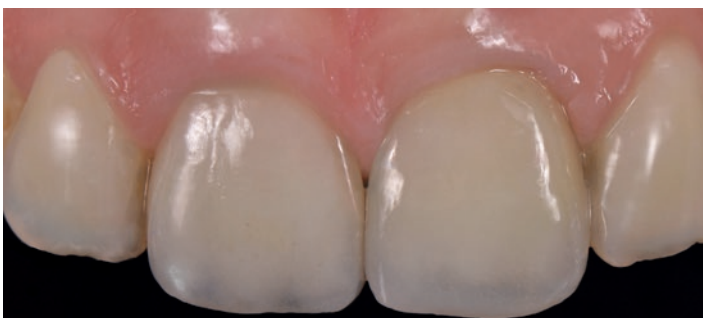Screw-retained crown



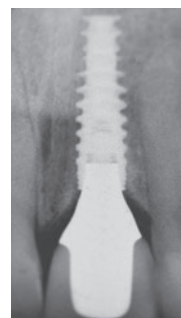
Clinical view following finalization.



Radiograph following finalization.



Excellent esthetic outcome at 8 years' follow-up



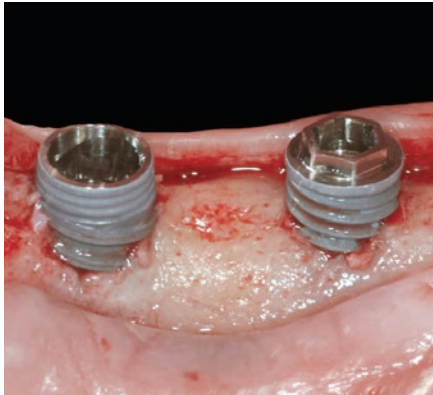
Radiograph at 8 years' follow-up

Images courtesy of Dr. Giacomo Fabbri, Italy.


Three-year post-loading results of a randomised, controlled, split-mouth trial comparing implants with different prosthetic interfaces and design in partially posterior edentulous mandibles

Pozzi A, Tallarico M, Moy PK


Eur J Oral Implantol 2014;7(1):47-61.



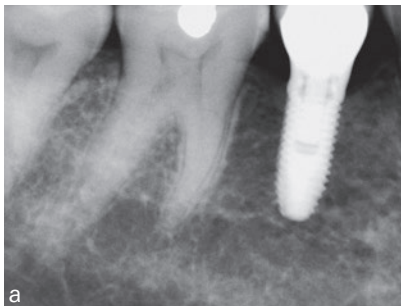Clinical view of the two investigated implant designs.



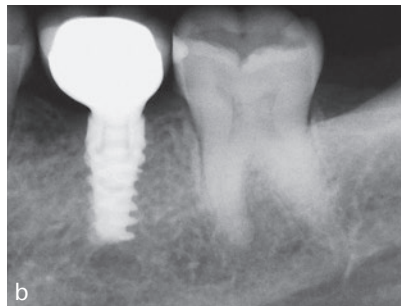
Characteristics of the two different implant designs and connections used in this study



Diagrams showing the measurement locations utilized in this investigation:
 VMBL = the distance from the most coronal margin of the implant collar (IC) and the top of the bone crest (BC)
 HVBL = the distance from the internal aspect of the socket wall at the level of the alveolar crest (IAC) to the implant surface (I).

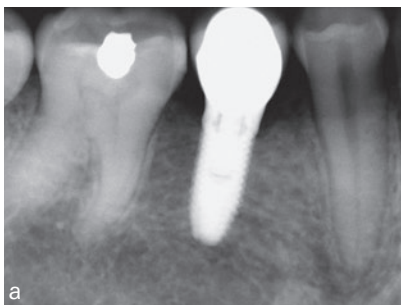


a

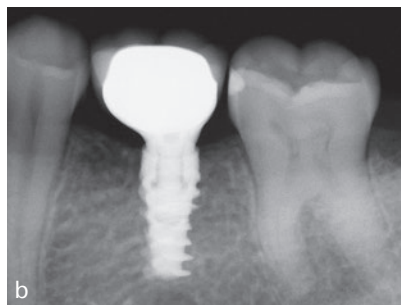


b

Periapical radiographs after 1 year in function:
 (a) NobelSpeedy Groovy implant (control group);
 (b) NobelActive implant (test group)

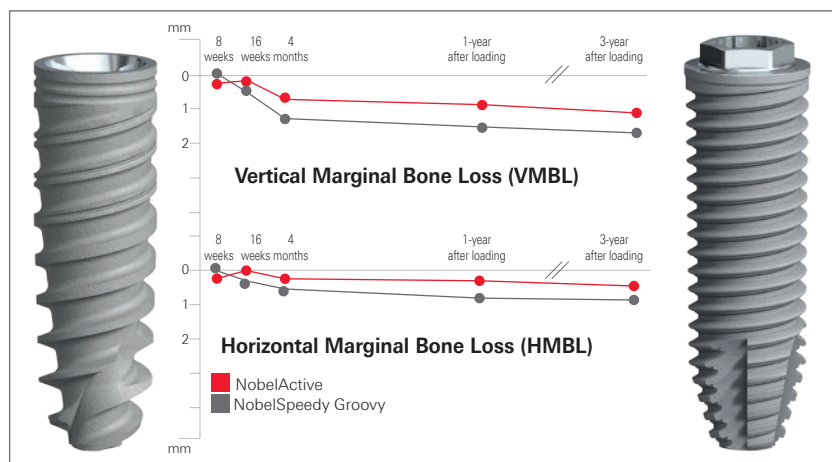


a

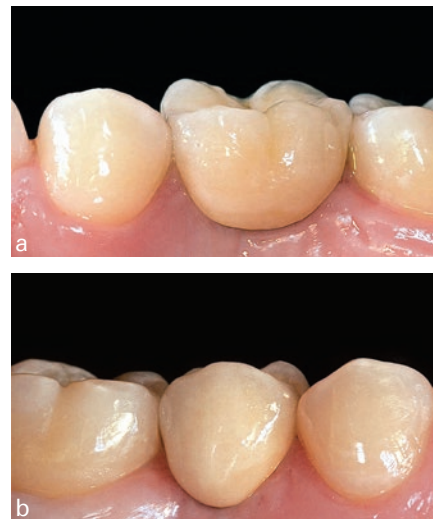

b

Periapical radiographs after 3 years in function:
 (a) NobelSpeedy Groovy implant (control group);
 (b) NobelActive implant (test group)



Graph showing the vertical and horizontal marginal bone loss from implant insertion to 3-year follow-up of all implants



Intraoral photographs after 3 years in function:
 (a) NobelSpeedy Groovy implant (control group);
 (b) NobelActive implant (test group).

Original abstract

Purpose: To compare the clinical and radiological outcomes of two implant designs with different prosthetic interfaces and neck configurations.

Materials and methods: Thirty-four partially edentate patients randomly received at least one NobelActive implant (Nobel Biocare, Goteborg, Sweden) with back-tapered collar, internal conical connection and platform shifting design, and one NobelSpeedy implant (Nobel Biocare) with external hexagon and flat-to-flat implant-abutment interface according to a split-mouth design. Follow-up continued to 3 years' post-loading. The primary outcome measures were the success rates of the implants and prostheses, and the occurrence of any surgical and prosthetic complications during the entire follow-up. Secondary outcome measures were: horizontal and vertical peri-implant marginal bone level (MBL) changes, resonance frequency analysis values at implant placement and loading (4 months), sulcus bleeding index (SBI) and plaque score (PS).

Results: No drop-out occurred. No implants and prostheses failures were observed to the 3-year follow-up. MBL changes were statistically significant different with better results for the NobelActive implants for both horizontal and vertical measurements ($p = 0.000$). After 3 years post-loading, the NobelActive implants underwent a mean vertical bone resorption of 0.66 mm, compared with 1.25 mm for the NobelSpeedy Groovy implants ($p = 0.000$); the mean horizontal bone resorption was 0.19 mm for the NobelActive implants and 0.60 mm for the NobelSpeedy Groovy implants ($p = 0.000$). A high ISQ value was found for both implants, and no statistically significant difference was found for ISQ mean values between interventions ($p = 0.941$ at baseline; $p = 0.454$ at implant-abutment connection; $p = 0.120$ at prosthesis delivery). All implants showed good periodontal health at the 3-year-in-function visit, with no significant differences between groups.

Conclusion: The results of this research suggest that in well-maintained patients, the MBL changes could be affected by the different implant design. After 4 months of unloaded healing, as well as after 3 years in function, both implants provided good results, however vertical and horizontal bone loss had statistically significant differences between the two groups (difference of 0.58 ± 0.10 mm for the vertical MBL, and 0.4 ± 0.05 mm for the horizontal MBL), with lower values in the NobelActive implants, compared to the NobelSpeedy Groovy implants.

TiUnite[®] implants with conical connection

Overview of studies

The following overview includes clinical studies using TiUnite implants with conical connection. The studies are ordered by follow-up time.

Only peer-reviewed publications are listed. Meeting abstracts, reviews, single case reports, technique descriptions and animal and in vitro tests are excluded. The total number of implants and patients included in this overview is over 14,300 and 2,500 respectively, with mean implant survival rate of 98.6%.^A

Only marginal bone level change of studies with implant level baseline are presented. For more information on these studies visit PubMed at pubmed.gov.

Reference	Mean follow-up time [years] ^B	Study type	Implant ^C	Indication/ study focus	No. of implants	No. of patients	Implant survival rate [%]	Mean change in marginal bone level (SD) [mm]
Jensen et al., 2016 ⁵⁷	5	Retrospective	NobelActive	Fully edentulous maxilla, Immediate-loading	158	39	94.9 ^D	NR
Li et al., 2017 ⁶³	5	Prospective	NobelActive	Fully edentulous maxilla & mandible, Extraction sites, All-on-4	28	NR	NR	NR
Cosyn et al., 2016 ³³	5	Prospective	NobelActive	Single tooth, Anterior & posterior maxilla, Cement- & screw-retained, Extraction sites, Immediate loading	22	22	94.1 ^D	-0.19 (0.3)
Cosyn et al., 2013 ⁶⁴								
Passos et al., 2016 ⁶⁵	5	Retrospective	NobelActive	Single tooth, Anterior maxilla & mandible	12	NR	100 ^D	NR
Babbush, 2015 ⁶⁶	4.5	Retrospective	NobelActive	Maxilla & mandible, Screw-retained, Healed & extraction sites, All-on-4	5002	NR	98.1	NR
Pozzi et al., 2015 ⁶⁷	4.1	Prospective	NobelActive	Fully edentulous maxilla & mandible, Screw-retrained, Healed sites, Immediate loading, Guided surgery	62	NR	100	NR
Pozzi and Moy, 2014 ⁶⁸	3.7	Prospective	NobelActive	Partially edentulous posterior maxilla, Immediate loading, Guided surgery	37	NR	97.3	NR
Pozzi et al., 2015 ⁶⁹	3.5	Retrospective	NobelActive	Fully edentulous maxilla & mandible, Healed & extraction sites, Immediate loading, Guided surgery	85	NR	100 ^D	NR

Reference	Mean follow-up time [years] ^B	Study type	Implant ^C	Indication/ study focus	No. of implants	No. of patients	Implant survival rate [%]	Mean change in marginal bone level (SD) [mm]
Babbush et al., 2014⁷⁰	3.4	Retrospective	NobelActive	Maxilla & Mandible, Anterior & Posterior, Cement & Screw, fully-edentulous, Healed & Extraction, All-on-4	60	15	98.3 ^D	NR
Pozzi, et al., 2015⁷¹	3.2	Prospective	NobelReplace CC	Maxilla & Mandible, Anterior & Posterior, Cement & Screw, Healed & Extraction, 1-stage, Immediate-Loading	118	54	98.3 ^D	-0.68 (0.6)
Demanet, et al., 2011⁷²	3	Retrospective	NobelActive	Maxilla & Mandible, Anterior & Posterior, Healed & Extraction, 1-stage & 2-stage	466	172	99.1	-0.39 (NR)
De Santis et al., 2016⁷³	3	Prospective	NobelActive	Maxilla & Mandible, Anterior & Posterior, Screw, 2-stage, Delayed-Loading	144	62	98.6	-0.70 (0.5)
Arnhart et al., 2012⁵⁹	3	Prospective	NobelActive	Maxilla & Mandible, Anterior & Posterior, Cement & Screw, Healed, 1-stage, Immediate-Loading	117	117	96 ^D	-0.89 (1.7) ^D
Kielbassa et al., 2009⁶⁰								
Kolinski et al., 2014⁵⁰	3	Prospective	NobelActive	Maxilla & Mandible, Anterior & Posterior, Screw, Extraction, 1-stage, Immediate-Loading	60	55	98.3	+0.30 (1.6)
McAllister et al., 2012⁷⁴								
Pozzi et al., 2014⁵¹	3	Prospective	NobelActive	Mandible, Posterior, Cement, single-tooth, Healed, 2-stage, Early-Loading	44	34	100	-0.67 (0.4)
Pozzi et al., 2014⁷⁵								
De Vico et al., 2011⁷⁶	2.1	Prospective	NobelActive	Maxilla & Mandible, Anterior & Posterior, Screw, fully-edentulous, Healed & Extraction, 1-stage, Immediate-Loading, Guided-Surgery, All-on-4	140	35	100	-0.72 @ 1 year (NR) ^D
Babbush and Brokloff, 2012⁵⁸	2	Retrospective	NobelActive	Maxilla & Mandible, Anterior & Posterior, Healed & Extraction, 1-stage & 2-stage	1001	293	97.4	NR
Babbush et al., 2011⁷⁷								
Drago, 2016⁷⁸	2	Retrospective	NobelActive	Maxilla & Mandible, Anterior & Posterior, screw, fully-edentulous, Healed & Extraction, 1-stage, Immediate-Loading	774	130	99.5	NR

Reference	Mean follow-up time [years] ^B	Study type	Implant ^C	Indication/ study focus	No. of implants	No. of patients	Implant survival rate [%]	Mean change in marginal bone level (SD) [mm]
Drago, 2016⁷⁹	2	Retrospective	NobelActive	Maxilla & Mandible, Anterior & Posterior, Screw, fully-edentulous, Healed & Extraction, Immediate-Loading, All-on-4	770	128	99.5	NR
Drago, 2016⁸⁰	2	Retrospective	NobelActive	Maxilla & Mandible, Anterior & Posterior, Screw, fully-edentulous, Healed & Extraction, 1-stage, Immediate-Loading, All-on-4	766	129	99.5	NR
Orentlicher et al., 2014⁸¹	2	Retrospective	NobelActive	Maxilla & Mandible, Anterior & Posterior, Healed & Extraction, Guided-Surgery	121	NR	95.87	NR
Ganeles et al., 2017⁸²	2	Prospective	NobelActive	Single-arm, single center, Maxilla, Anterior & Posterior, Single-tooth, Extraction sites, 1-stage	15	15	100	+0.83 (2.73)
Pozzi and Mura, 2016⁸³	1.9	Retrospective	NobelReplace CC	Maxilla & Mandible, Anterior & Posterior, Cement & Screw, Healed & Extraction	148	64	99.3	-0.71 (1.5)
Aires and Berger, 2016⁸⁴	1.6	Retrospective	NobelActive	Maxilla & Mandible, Anterior & Posterior, Screw, fully-edentulous, Healed & Extraction, 1-stage & 2-stage, Guided-Surgery	1657	228	99.4	NR
Younes et al., 2016⁸⁵	1.6	Retrospective	NobelActive	Maxilla, Posterior, Cement & Screw, 1-stage & 2-stage	165	57	98.2 ^D	NR
Wessing et al., 2016⁸⁶	1.53	Retrospective	NobelActive, NobelReplace CC	Maxilla & Mandible, partially-edentulous, Healed, 1-stage & 2-stage, Delayed-Loading	6	NR	100	NR
Pozzi et al., 2016⁸²	1.4	Prospective	NobelReplace CC	Maxilla & Mandible, Anterior & Posterior, Screw, fully-edentulous, Healed, Delayed-Loading, Guided-Surgery	72	18	100	-0.29 (0.2)
Babbush et al., 2016⁸⁷	1.3	Retrospective	NobelActive	Maxilla & Mandible, Anterior & Posterior, fully-edentulous, Healed & Extraction, 1-stage, Immediate-Loading, All-on-4	856	169	99.8	-0.14 (0.6)
MacLean et al., 2016⁸⁸	1.3	Retrospective	NobelActive	Maxilla & Mandible, Anterior, Cement & Screw, single-tooth, Healed & Extraction, 1-stage & 2-stage	44	34	96.4	-0.36 (0.9)

Reference	Mean follow-up time [years] ^B	Study type	Implant ^C	Indication/ study focus	No. of implants	No. of patients	Implant survival rate [%]	Mean change in marginal bone level (SD) [mm]
Gultekin et al., 2013⁵²	1.25	Prospective	NobelActive	Maxilla & Mandible, Anterior & Posterior, Cement, partially-edentulous, Healed, 2-stage, Delayed-Loading, Guided-Surgery	43	NR	100	-0.35 (0.1)
Polizzi G et al., 2016⁵³	2.4	Retrospective	NobelActive	Maxilla, Anterior & Posterior, Healed & Extraction, Immediate-Loading, Guided-Surgery	160	27	99.4	-0.58 (0.98)
Babbush and Kanawati, 2015⁸⁹	1.0	Retrospective	NobelActive	Maxilla & Mandible, Anterior & Posterior, Healed & Extraction	262	65	98.1	NR
Yamada et al., 2015⁵⁵	1	Prospective	NobelActive (NP, RP)	Maxilla, Anterior & Posterior, Screw, fully-edentulous, Healed, 1-stage, Immediate-Loading, Guided-Surgery	290	50	98.6	-0.32 (0.4)
Babbush et al., 2013⁵⁶	1	Retrospective	NobelActive	Maxilla & Mandible, Anterior & Posterior, fully-edentulous, Healed & Extraction, 1-stage & 2-stage	227	53	98.7	NR
Esposito et al., 2017⁹⁰	1	Prospective	NobelActive	Maxilla & Mandible, single-tooth Immediate-Loading, Immediate-delayed & delayed loading	210	210	95.4	-0.28 (0.16)
Fugl et al., 2016⁶¹	1	Prospective	NobelReplace CC	Maxilla, Anterior & Posterior, Cement & Screw, single-tooth, Healed, 1-stage, Immediate-Loading	102	97	99	-0.85 (1.4)
Galindo and Butura, 2012⁹¹	1	Retrospective	NobelActive	Mandible, Anterior & Posterior, Screw, fully-edentulous, Mixed, 1-stage, Immediate-Loading, Guided-Surgery, All-on-4	60	183	100 ^D	≤ -1.0 (NR)
Meloni et al., 2017⁹²	1	Prospective	NobelReplace CC	Single-arm, Prospective, Single center, Maxilla & Mandible, Posterior, Single-tooth, partially edentulous & fully edentulous, Healed, 2-stage, Delayed loading	55	18	100	-1.03 (0.21)
Cosyn et al., 2015⁹³	1	Prospective	NobelActive	Maxilla, Anterior & Posterior, Screw, single-tooth, Healed, 1-stage, Delayed-Loading	47	47	100	-0.48 (0.5)

Reference	Mean follow-up time [years] ^B	Study type	Implant ^C	Indication/ study focus	No. of implants	No. of patients	Implant survival rate [%]	Mean change in marginal bone level (SD) [mm]
Slagter et al., 2015⁹⁴	1	Prospective	NobelActive	Maxilla, Anterior & Posterior, Cement & Screw, single-tooth, Extraction, 1-stage & 2-stage	40	40	100	-0.70 (NR) ^D
Slagter et al., 2016⁹⁵	1	Prospective	NobelActive	Maxilla, Anterior, Cement & Screw, single-tooth, Healed & Extraction, 2-stage, Delayed-Loading	40	40	100	-0.53 (NR) ^D
Cristalli et al., 2015⁹⁶	1	Prospective	NobelActive	Maxilla & Mandible, Anterior & Posterior, Cement, single-tooth, Extraction, 1-stage, Immediate-Loading	25	24	92	-0.33 (NR) ^D
Rokn et al., 2015⁹⁷	1	Prospective	NobelActive	Mandible, Posterior, single-tooth	25	NR	100 ^D	-0.68 (0.5)
Bruno et al., 2014⁹⁸	1	Prospective	NobelActive	Maxilla, Anterior & Posterior, single-tooth, Extraction, 1-stage, Immediate-Loading	5	3	100 ^D	NR

Source: Nobel Biocare data on file. TiUnite literature search. Clinical research department, July 31, 2017.

A: Arithmetic means weighted by number of initially placed implants (implant survival rate) or number of patients treated (prosthetic survival rate).

B: Where the mean follow-up time was not available the reported follow-up time was used (minimum one-year follow-up). Last radiological follow-up for mean marginal bone level change may differ from the overall study follow-up.

C: Minimum 10 implants, 1 year of follow-up.

D: The percentage of surviving implants/prostheses or MBL was calculated.

NR: Not reported.

References

- Hall J, Lausmaa J. Properties of a new porous oxide surface on titanium implants. *Appl Osseointegrat Res* 2000;1(1):5–8.
- He J, Zhou W, Zhou X, et al. The anatase phase of nanopography titania plays an important role on osteoblast cell morphology and proliferation. *J Mater Sci Mater Med*. 2008;19(11):8.
- Albrektsson T, Johansson C, Lundgren A-K, et al. Experimental studies on oxidized implants. A histomorphometrical and biomechanical analysis. *Appl Osseointegrat Research* 2000;1(1):21–24.
- Omar OM, Lenneras ME, Suska F, et al. The correlation between gene expression of proinflammatory markers and bone formation during osseointegration with titanium implants. *Biomaterials* 2011;32(2):374–386.
- Schupbach P, Glauser R, Rocci A, et al. The human bone-oxidized titanium implant interface: A light microscopic, scanning electron microscopic, back-scatter scanning electron microscopic, and energy-dispersive x-ray study of clinically retrieved dental implants. *Clin Implant Dent Relat Res* 2005;7(Suppl 1):S36–43.
- Rocci A, Martignoni M, Burgos PM, et al. Histology of retrieved immediately and early loaded oxidized implants: light microscopic observations after 5 to 9 months of loading in the posterior mandible. *Clin Implant Dent Relat Res* 2003;5(Suppl 1):88–98.
- Omar O, Svensson S, Zoric N, et al. In vivo gene expression in response to anodically oxidized versus machined titanium implants. *J Biomed Mater Res A* 2010;92(4):1552–1566.
- Lenneras M, Palmquist A, Norlindh B, et al. Oxidized titanium implants enhance osseointegration via mechanisms involving RANK/RANKL/OPG regulation. *Clin Implant Dent Relat Res* 2015;17(Suppl 2):e486–e500.
- Karl M, Albrektsson T. Clinical performance of dental implants with a moderately rough (TiUnite) surface: a meta-analysis of prospective clinical studies. *Int J Oral Maxillofac Implants* 2017;32(4):717–734.
- Östman PO, Hellman M, Sennerby L. Ten years later. Results from a prospective single-centre clinical study on 121 oxidized (TiUnite™) Brånemark implants in 46 patients. *Clin Implant Dent Relat Res* 2012;14(6):852–860.
- Ma S, Tawse-Smith A, De Silva RK, et al. Maxillary three-implant overdentures opposing mandibular two-implant overdentures: 10-year surgical outcomes of a randomized controlled trial. *Clin Implant Dent Relat Res* 2016;18(3):527–544.
- Mozzati M, Galesio G, Del Fabbro M. Long-term (9–12 years) outcomes of titanium implants with an oxidized surface: a retrospective investigation on 209 implants. *J Oral Implantol* 2015;41(4):437–443.
- Zou D, Huang W, Wang F, et al. Autologous ilium grafts: long-term results on immediate or staged functional rehabilitation of mandibular segmental defects using dental implants after tumor resection. *Clin Implant Dent Relat Res* 2015;17(4):779–789.
- Glauser R. Implants with an oxidized surface placed predominately in soft bone quality and subjected to immediate occlusal loading: results from an 11-year clinical follow-up. *Clin Implant Dent Relat Res* 2016;18(3):429–438.
- Jemt T, Olsson M, Franke Stenport V. Incidence of first implant failure: a retrospective study of 27 years of implant operations at one specialist clinic. *Clin Implant Dent Relat Res* 2015;17(Suppl 2):e501–e510.
- Jemt T. Single-implant survival: more than 30 years of clinical experience. *Int J Prosthodont* 2016;30(6):551–558.
- Chrcanovic BR, Albrektsson T, Wennerberg A. Turned versus anodised dental implants: a meta-analysis. *J Oral Rehabil* 2016;43(9):716–728.
- Misch CE, Perel ML, Wang HL, et al. Implant success, survival, and failure: the International Congress of Oral Implantologists (ICOI) Pisa Consensus Conference. *Implant Dent* 2008;17(1):5–15.
- Zarb GA, Albrektsson T. Consensus report: towards optimized treatment outcomes for dental implants. *J Prosthet Dent* 1998;80(6):641.
- Pozzi A, Mura P. Clinical and radiologic experience with moderately rough oxidized titanium implants: up to 10 years of retrospective follow-up. *Int J Oral Maxillofac Implants* 2014;29(1):152–161.
- Imburgia M, Del Fabbro M. Long-term retrospective clinical and radiographic follow-up of 205 Branemark System Mk III TiUnite implants submitted to either immediate or delayed loading. *Implant Dent* 2015;24(5):533–540.
- Froum SJ, Khouly I. Survival rates and bone and soft tissue level changes around one-piece dental implants placed with a flapless or flap protocol: 8.5-year results. *Int J Periodontics Restorative Dent* 2017;37(3):327–337.
- Froum SJ, Cho SC, Elian N, et al. Survival rate of one-piece dental implants placed with a flapless or flap protocol-a randomized, controlled study: 12-month results. *Int J Periodontics Restorative Dent* 2011;31(6):591–601.
- Polizzi G, Gualini F, Friberg B. A two-center retrospective analysis of long-term clinical and radiologic data of TiUnite and turned implants placed in the same mouth. *Int J Prosthodont* 2013;26(4):350–358.
- Wagenberg B, Froum SJ. Long-term bone stability around 312 rough-surfaced immediately placed implants with 2–12-year follow-up. *Clin Implant Dent Relat Res* 2015;17(4):658–666.
- Gelb D, McAllister B, Nummikoski P, del Fabbro M. Clinical and radiographic evaluation of Brånemark implants with an anodized surface following seven-to-eight years of functional loading. *Int J Dent* 2013;583567.
- Turkylmaz I, Tozum TF, Fuhrmann DM, Turner C. Seven-year follow-up results of tiunite implants supporting mandibular overdentures: early versus delayed loading. *Clin Implant Dent Relat Res* 2012;14(Suppl 1):e83–e90.
- Meloni SM, Tallarico M, Pisano M, et al. Immediate loading of fixed complete denture prosthesis supported by 4–8 implants placed using guided surgery: a 5-year prospective study on 66 patients with 356 implants. *Clin Implant Dent Relat Res* 2017;19(1):195–206.
- Polizzi G, Cantoni T. Five-year follow-up of immediate fixed restorations of maxillary implants inserted in both fresh extraction and healed sites using the NobelGuide™ system. *Clin Implant Dent Relat Res* 2015;17(2):221–233.
- Alfadda SA, Attard NJ, David LA. Five-year clinical results of immediately loaded dental implants using mandibular overdentures. *Int J Prosthodont* 2009;22(4):368–373.
- Calandriello R, Tomatis M. Immediate occlusal loading of single lower molars using Brånemark System(R) Wide platform TiUnite implants: a 5-year follow-up report of a prospective clinical multicenter study. *Clin Implant Dent Relat Res* 2011;13(4):311–318.
- Cehreli MC, Uysal S, Akca K. Marginal bone level changes and prosthetic maintenance of mandibular overdentures supported by 2 implants: a 5-year randomized clinical trial. *Clin Implant Dent Relat Res* 2010;12(2):114–121.
- Cosyn J, Eghbali A, Hermans A, et al. A 5-year prospective study on single immediate implants in the aesthetic zone. *J Clin Periodontol* 2016;43(8):702–709.
- Lopes A, Malo P, de Araujo Nobre M, et al. The NobelGuide(R) All-on-4(R) Treatment Concept for rehabilitation of edentulous jaws: a prospective report on medium- and long-term outcomes. *Clin Implant Dent Relat Res* 2015;17(S2):e406–e416.
- Malo P, Nobre Mde A, Lopes A, Ferro A, Gravito I. Immediate loading of implants placed in patients with untreated periodontal disease: A 5-year prospective cohort study. *Eur J Oral Implantol* 2014;7(3):295–304.
- Mura P. Immediate loading of tapered implants placed in postextraction sockets: retrospective analysis of the 5-year clinical outcome. *Clin Implant Dent Relat Res* 2012;14(4):565–574.
- Petersson P, Sennerby L. A 5-year retrospective study on Replace Select Tapered dental implants. *Clin Implant Dent Relat Res* 2015;17(2):286–295.
- Albrektsson T, Buser D, Sennerby L. Crestal bone loss and oral implants. *Clin Implant Dent Relat Res* 2012;14(6):783–791.
- Haidich A. Meta-analysis in medical research. *Hippokratia* 2010;14(Suppl 1):9.
- Berglundh T, Gotfredsen K, Zitzmann NU, et al. Spontaneous progression of ligature induced peri-implantitis at implants with different surface roughness: an experimental study in dogs. *Clin Oral Impl Res* 2007;18(5):655–661.
- Derks J, Tomasi C. Peri-implant health and disease. A systematic review of current epidemiology. *J Clin Periodontol* 2015;42(Suppl 16):S158–S171.
- Derks J, Hakansson J, Wennstrom JL, et al. Effectiveness of implant therapy analyzed in a Swedish population: early and late implant loss. *J Dent Res* 2015;94(3 Suppl):44S–51S.
- Albrektsson T, Canullo L, Cochran D, De Bruyn H. “Peri-implantitis”: a complication of a foreign body or a man-made “disease”. Facts and fiction. *Clin Implant Dent Relat Res* 2016;18(4):840–849.
- Glauser R, Schupbach P, Gottlow J, Hammerle CH. Periimplant soft tissue barrier at experimental one-piece mini-implants with different surface topography in humans:

- A light-microscopic overview and histometric analysis. *Clin Implant Dent Relat Res* 2005;7(Suppl 1):S44–51.
45. Schupbach P, Glauser R. The defense architecture of the human periimplant mucosa: a histological study. *J Prosthet Dent* 2007;97(6 Suppl):S15–25.
 46. den Hartog L, Meijer HJA, Vissink A, Raghoobar GM. Anterior single implants with different neck designs: 5 Year results of a randomized clinical trial. *Clin Implant Dent Relat Res* 2017;19(4):717–24.
 47. Bassetti R, Kaufmann R, Ebinger A, Mericske-Stern R, Enkling N. Is a grooved collar implant design superior to a machined design regarding bone level alteration? An observational pilot study. *Quintessence Int* 2014;45(3):221–229.
 48. Glauser R, Portmann M, Ruhstaller P, et al. Stability measurements of immediately loaded machined and oxidized implants in the posterior maxilla. A comparative clinical study using resonance frequency analysis. *Appl Osseointegrat Res* 2001;2:27–29.
 49. Zipprich H, Miatke S, Hmaidouch R, Lauer HC. A new experimental design for bacterial microleakage investigation at the implant-abutment interface: an in vitro study. *Int J Oral Maxillofac Implants* 2016;31(1):37–44.
 50. Kolinski ML, Cherry JE, McAllister BS, et al. Evaluation of a variable-thread tapered implant in extraction sites with immediate temporization: a 3-year multi-center clinical study. *J Periodontol* 2014;85(3):386–394.
 51. Pozzi A, Tallarico M, Moy PK. Three-year post-loading results of a randomised, controlled, split-mouth trial comparing implants with different prosthetic interfaces and design in partially posterior edentulous mandibles. *Eur J Oral Implantol* 2014;7(1):47–61.
 52. Gultekin BA, Gultekin P, Leblebicioglu B, Basegmez C, Yalcin S. Clinical evaluation of marginal bone loss and stability in two types of submerged dental implants. *Int J Oral Maxillofac Implants* 2013;28(3):815–23.
 53. Polizzi G, Cantoni T, Pasini E, Tallarico M. Immediate loading of variable-thread expanding tapered-body implants placed into maxillary post-extraction or healed sites using a guided surgery approach: An up-to-five-year retrospective analysis. *J Oral Science Rehabilitation* 2016;2(3):50–60.
 54. Irinakis T, Wiebe C. Clinical evaluation of the NobelActive implant system: a case series of 107 consecutively placed implants and a review of the implant features. *J Oral Implantol* 2009;35(6):283–288.
 55. Yamada J, Kori H, Tsukiyama Y, et al. Immediate loading of complete-arch fixed prostheses for edentulous maxillae after flapless guided implant placement: a 1-year prospective clinical study. *Int J Oral Maxillofac Implants* 2015;30(1):184–93.
 56. Babbush CA, Kanawati A, Brokloff J. A new approach to the all-on-four treatment concept using narrow platform NobelActive implants. *J Oral Implantol* 2013;39(3):314–325.
 57. Jensen OT, Ringeman JL, Adams MW, Gregory N. Reduced arch length as a factor for four implant immediate function in the maxilla: A technical note and report of 39 patients followed for 5 years. *J Oral Maxillofac Surg* 2016;74(12):2379–2384.
 58. Babbush CA, Brokloff J. A single-center retrospective analysis of 1001 consecutively placed NobelActive implants. *Implant Dent* 2012;21(1):28–35.
 59. Arnhart C, Kielbassa AM, Martinez-de Fuentes R, et al. Comparison of variable-thread tapered implant designs to a standard tapered implant design after immediate loading. A 3-year multicentre randomised controlled trial. *Eur J Oral Implantol* 2012;5(2):123–136.
 60. Kielbassa AM, Martinez-de Fuentes R, Goldstein M, et al. Randomized controlled trial comparing a variable-thread novel tapered and a standard tapered implant: interim one-year results. *J Prosthet Dent* 2009;101(5):293–305.
 61. Fugl A, Zechner W, Pozzi A, et al. An open prospective single cohort multicenter study evaluating the novel, tapered, conical connection implants supporting single crowns in the anterior and premolar maxilla: interim 1-year results. *Clin Oral Investig* 2017;21(6):2133–2142.
 62. Pozzi A, Tallarico M, Moy PK. Four-implant overdenture fully supported by a CAD/CAM titanium bar: A single-cohort prospective 1-year preliminary study. *J Prosthet Dent* 2016;116(4):516–523.
 63. Li S, Di P, Zhang Y, Lin Y. Immediate implant and rehabilitation based on All-on-4 concept in patients with generalized aggressive periodontitis: A medium-term prospective study. *Clin Implant Dent Relat Res* 2017;19(3):559–571.
 64. Cosyn J, De Bruyn H, Cleymaet R. Soft tissue preservation and pink aesthetics around single immediate implant restorations: a 1-year prospective study. *Clin Implant Dent Relat Res* 2013;15(6):847–857.
 65. Passos SP, Linke B, Larjava H, French D. Performance of zirconia abutments for implant-supported single-tooth crowns in esthetic areas: a retrospective study up to 12-year follow-up. *Clin Oral Implants Res* 2016;27(1):47–54.
 66. Babbush CA. A multi-center review of 53,802 implants utilized in over 13,000 jaws for All-On-4 reconstruction. *AO* 2015;108(4):28–31.
 67. Pozzi A, Tallarico M, Barlattani A. Monolithic lithium disilicate full-contour crowns bonded on CAD/CAM zirconia complete-arch implant bridges with 3 to 5 years of follow-up. *J Oral Implantol* 2015;41(3):450–458.
 68. Pozzi A, Moy PK. Minimally invasive transcresal guided sinus lift (TGSL): a clinical prospective proof-of-concept cohort study up to 52 months. *Clin Implant Dent Relat Res* 2014;16(4):582–593.
 69. Pozzi A, Holst S, Fabbri G, Tallarico M. Clinical reliability of CAD/CAM cross-arch zirconia bridges on immediately loaded implants placed with computer-assisted/template-guided surgery: a retrospective study with a follow-up between 3 and 5 years. *Clin Implant Dent Relat Res* 2015;17(Suppl 1):e86–e96.
 70. Babbush CA, Kanawati A, Kotsakis GA, Hinrichs JE. Patient-related and financial outcomes analysis of conventional full-arch rehabilitation versus the All-on-4 Concept: a cohort study. *Implant Dent* 2014;23(2):218–224.
 71. Pozzi A, Tallarico M, Moy PK. Immediate loading with a novel implant featured by variable-threaded geometry, internal conical connection and platform shifting: Three-year results from a prospective cohort study. *Eur J Oral Implantol* 2015;8(1):51–63.
 72. Demanet M, Merheb J, Simons WF, Leroy R, Quirynen M. The outcome of a novel tapered implant in a private practice limited to Periodontology. *Le Dentiste* 2011;426:22–25.
 73. De Santis D, Cucchi A, Rigoni G, Longhi C, Nocini PF. Relationship between primary stability and crestal bone loss of implants placed with high insertion torque: a 3-year prospective study. *Int J Oral Maxillofac Implants* 2016;31(5):1126–1134.
 74. McAllister BS, Cherry JE, Kolinski ML, et al. Two-year evaluation of a variable-thread tapered implant in extraction sites with immediate temporization: a multicenter clinical trial. *Int J Oral Maxillofac Implants* 2012;27(3):611–618.
 75. Pozzi A, Agliardi E, Tallarico M, Barlattani A. Clinical and radiological outcomes of two implants with different prosthetic interfaces and neck configurations: randomized, controlled, split-mouth clinical trial. *Clin Implant Dent Relat Res* 2014;16(1):96–106.
 76. De Vico G, Bonino M, Spinelli D, et al. Rationale for tilted implants: FEA considerations and clinical reports. *Oral Implantol (Rome)* 2011;4(3-4):23–33.
 77. Babbush C, Kutsko G, Brokloff J. The All-on-Four Immediate Function treatment concept with NobelActive implants – A retrospective study. *J Oral Implantol* 2011;37(4):431–445.
 78. Drago C. Ratios of cantilever lengths and anterior-posterior spreads of definitive hybrid full-arch, screw-retained prostheses: results of a clinical study. *J Prosthodont* 2016; doi: 10.1111/jopr.12519.
 79. Drago C. Cantilever lengths and anterior-posterior spreads of interim, acrylic resin, full-arch screw-retained prostheses and their relationship to prosthetic complications. *J Prosthodont* 2017;26(6):502–507.
 80. Drago C. Frequency and type of prosthetic complications associated with interim, immediately loaded full-arch prostheses: a 2-year retrospective chart review. *J Prosthodont* 2016;25(6):433–439.
 81. Orentlicher G, Horowitz A, Goldsmith D, et al. Cumulative survival rate of implants placed “fully guided” using ct-guided surgery: a 7-year retrospective study. *Compend Contin Educ Dent* 2014;35(8):590–597.
 82. Ganeles J, Norkin FJ, Zfaz S. Single-tooth implant restorations in fresh extraction sockets of the maxillary esthetic zone: two-year results of a prospective cohort study. *Int J Periodontics Restorative Dent* 2017;37(2):e154–e162.
 83. Pozzi A, Mura P. Immediate loading of conical connection implants: up-to-2-year retrospective clinical and radiologic study. *Int J Oral Maxillofac Implants* 2016;31(1):142–152.
 84. Aires I, Berger J. Planning implant placement on 3D stereolithographic models applied with immediate loading of implant-supported hybrid prostheses after multiple extractions: a case series. *Int J Oral Maxillofac Implants* 2016;31(1):172–178.
 85. Younes F, Eghbali A, De Troyer S, et al. Marginal and apical bone stability after staged sinus floor augmentation using bone condensing implants with variable-thread design: a two-dimensional analysis. *Int J Oral Maxillofac Surg* 2016;45(9):1135–1141.

86. Wessing B, Emmerich M, Bozkurt A. Horizontal ridge augmentation with a novel resorbable collagen membrane: a retrospective analysis of 36 consecutive patients. *Int J Periodontics Restorative Dent* 2016;36(2):179–187.
87. Babbush CA, Kanawati A, Kotsakis GA. Marginal bone stability around tapered, platform-shifted implants placed with an immediately loaded four-implant-supported fixed prosthetic concept: a cohort study. *Int J Oral Maxillofac Implants* 2016;31(3):643–650.
88. MacLean S, Hermans M, Villata L, et al. A retrospective multicenter case series evaluating a novel 3.0-mm expanding tapered body implant for the rehabilitation of missing incisors. *Quintessence Int* 2016;47(4):297–306.
89. Babbush CA, Kanawati A. Clinical evaluation of 262 osseointegrated implants placed in sites grafted with calcium phosphosilicate putty: a retrospective study. *J Oral Implantol* 2015 Feb;41(1):63–9.
90. Esposito M, Zucchelli G, Cannizzaro G, et al. Immediate, immediate-delayed (6 weeks) and delayed (4 months) post-extractive single implants: 1-year post-loading data from a randomised controlled trial. *Eur J Oral Implantol* 2017;10(1):11–26.
91. Galindo DF, Butura CC. Immediately loaded mandibular fixed implant prostheses using the all-on-four protocol: a report of 183 consecutively treated patients with 1 year of function in definitive prostheses. *Int J Oral Maxillofac Implants* 2012;27(3):628–33.
92. Meloni SM, Jovanovic SA, Urban I, et al. Horizontal ridge augmentation using GBR with a native collagen membrane and 1:1 ratio of particulated xenograft and autologous bone: a 1-year prospective clinical study. *Clin Implant Dent Relat Res* 2017;19(1):38–45.
93. Cosyn J, Pollaris L, Van der Linden F, De Bruyn H. Minimally invasive single implant treatment (M.I.S.I.T.) based on ridge preservation and contour augmentation in patients with a high aesthetic risk profile: one-year results. *J Clin Periodontol* 2015;42(3):398–405.
94. Slagter KW, Meijer HJ, Bakker NA, Vissink A, Raghoebar GM. Feasibility of immediate placement of single-tooth implants in the aesthetic zone: a 1-year randomized controlled trial. *J Clin Periodontol* 2015;42(8):773–782.
95. Slagter KW, Meijer HJ, Bakker NA, Vissink A, Raghoebar GM. Immediate single-tooth implant placement in bony defects in the esthetic zone: a 1-year randomized controlled trial. *J Periodontol* 2016;87(6):619–629.
96. Cristalli MP, Marini R, La Monaca G, et al. Immediate loading of post-extractive single-tooth implants: a 1-year prospective study. *Clin Oral Implants Res* 2015;26(9):1070–1079.
97. Rohn AR, Badri S, Rasouli Ghahroudi AA, et al. Comparison of bone loss around bone platform shift and non-bone platform shift implants after 12 months. *J Dent (Tehran)* 2015;12(3):183–187.
98. Bruno V, O'Sullivan D, Badino M, Catapano S. Preserving soft tissue after placing implants in fresh extraction sockets in the maxillary esthetic zone and a prosthetic template for interim crown fabrication: A prospective study. *J Prosthet Dent* 2014;111(3):195–202.

